





MASSACHUSETTS  
GENERAL HOSPITAL



HARVARD  
MEDICAL SCHOOL

# Brain Circuitries in Basic and Clinical Neuroscience

**Seventh International Conference on Creative Content Technologies,  
ComputerWorld 2015, March 24, 2015 - Nice, France**



**Nikos Makris, M.D., Ph.D.**

**Center for Morphometric Analysis**


**Departments of Psychiatry and Neurology**

**Massachusetts General Hospital**

**Harvard Medical School**

# Disclosures of Potential Conflicts

Source	Consultant	Advisory Board	Stock or Equity >\$10,000	Speakers' Bureau	Research Support	Honorarium for this talk or meeting	Expenses related to this talk or meeting
<b>NIA-NIMH (RO1) (Aging)</b>					<b>X</b>		
<b>MGH-MAC Core (Multiple Projects)</b>					<b>X</b>		
<b>NIH (R21) (Neurodegeneration-FTD)</b>					<b>X</b>		
<b>NIH (R21) (Neurodegeneration-FTD and ALS)</b>					<b>X</b>		
<b>NIH (R21) (Modeling Deep Brain Stimulation and MRI safety)</b>					<b>X</b>		
<b>Departmental</b>					<b>X</b>		



Center for Morphometric Analysis

(CMA)-MGH collaborating PIs

**Marek Kubicki, M.D., Ph.D. (BWH/HMS)**

**Bradford Dickerson, M.D. (MGH/HMS)**

**Giorgio Bonmassar, Ph.D. (MGH/HMS)**

**Jill Goldstein, Ph.D. (BWH/HMS)**

**Larry Seidman, Ph.D.(BIDMC/MMHC/HMS)**

**Gordon Harris, Ph.D. (MGH/HMS)**

**Scott Rauch, M.D. (McLean/HMS)**

**Scott Lukas, Ph.D. (McLean/HMS)**

**Joseph Biederman, M.D. (MGH/HMS)**

**Marlene Oscar-Berman, Ph.D.(BUSM)**

**Deepak Pandya, M.D. (BUSM)**

**Douglas Rosene, Ph.D. (BUSM)**

**Martha Shenton, Ph.D. (BWH/HMS)**

**David Kennedy, Ph.D.(UMassMS)**

**David Caplan, M.D., Ph.D. (MGH/HMS)**

**Bruce Rosen, M.D., Ph.D. (MGH/HMS)**

**Helen Grant, M.D., Ph.D.(Children's//HMS)**

**Hans Breiter, M.D.(NWU)**

**Anne Blood, Ph.D. (MGH/HMS)**

Harvard Medical School affiliated Hospitals

Massachusetts General Hospital (MGH)

Brigham and Women's Hospital (BWH)

McLean Hospital

Beth Israel Deaconess Medical Center (BIDMC)

Mass Mental Health Center (MMHC)

Children's Hospital

Center for Morphometric Analysis (CMA)-MGH Core

**Nikos Makris, M.D., Ph.D. (Director)**

**Verne Caviness, M.D., Ph.D. (Founding Director)**

**George Papadimitriou, B.Sc. (Computer Science)**


**Lichen Liang, Ph.D. (MRI Engineering, Modeling)**

**Takeshi Takahashi, M.D., Ph.D. (Functional Conn.)**

**Isaac Ng, B.A. (RA)**

**Anni Zhu, B.A. (RA)**

**Yeetou Kao (RA)**





Nikos Makris, M.D., Ph.D. (MGH/BWH/McLean/HMS)

Verne Caviness, M.D., Ph.D. (MGH/HMS)

Marek Kubicki, M.D., Ph.D. (BWH/HMS)

Bradford Dickerson, M.D. (MGH/HMS)

**Giorgio Bonmassar, Ph.D. (MGH/HMS)**

Jill Goldstein, Ph.D. (BWH/HMS)

Larry Seidman, Ph.D. (BIDMC/MMHC/HMS)

Gordon Harris, Ph.D. (MGH/HMS)

Scott Rauch, M.D. (McLean/HMS)

Scott Lukas, Ph.D. (McLean/HMS)

Joseph Biederman, M.D. (MGH/HMS)

Marlene Oscar-Berman, Ph.D. (BUSM)

Deepak Pandya, M.D. (BUSM)

Douglas Rosene, Ph.D. (BUSM)

Martha Shenton, Ph.D. (BWH/HMS)

David Kennedy, Ph.D. (UMassMS)

David Caplan, M.D., Ph.D. (MGH/HMS)

Bruce Rosen, M.D., Ph.D. (MGH/HMS)

Helen Grant, M.D., Ph.D. (Children's/HMS)

Hans Breiter, M.D. (NWU)

Anne Blood, Ph.D. (MGH/HMS)

**Brain Connectivity/Aging/Neurodegeneration/Addiction/ADHD/Stroke/ITD**

**Brain Development/Laptop Imaging Technology Development/Stroke**

**Schizophrenia/Imaging Technology Development/Aging/Brain Connectivity**

**Neurodegeneration/Aging/ITD/Brain Connectivity**

**Technology Development/MRI Safety/Deep Brain Stimulation**

**Stress Response/Sexual Dimorphisms/Aging/MDD/Schizophrenia**

**Schizophrenia/MDD/BPD/ADHD/Resting State Brain Connectivity**

**3D Imaging Visualizations Technology Development/Alcohol Dependence**

**OCD/PTSD/Anxiety Disorder/Neurosurgery**

**Nicotine Dependence/Alcohol Dependence**

**Attention Deficit/Hyperactivity Disorder (ADHD)/Bipolar Disorder (BPD)**

**Alcohol Dependence**

**Brain Connectivity**

**Aging in the Rhesus Monkey/Monkey Brain Connectivity**

**Traumatic Brain Injury/Imaging Technology Development**

**Neuroinformatics/Imaging Databasing**

**Stroke/Aphasia Research**



**Imaging Technology Development (ITD)/Program in Acupuncture Research**

**Brain Development**

**Cocaine Dependence**


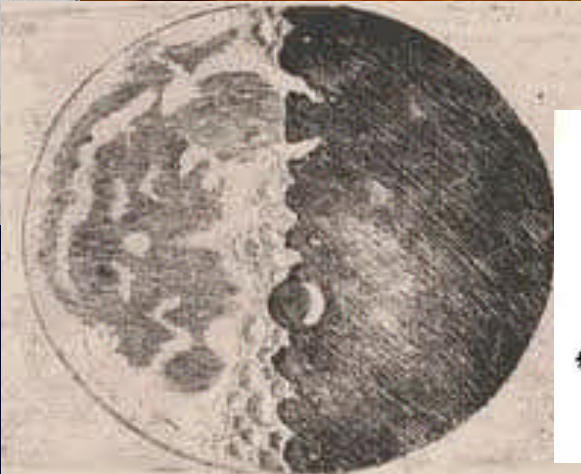

**Dystonia Research**

**Some discoveries are breakthroughs in knowledge and others in technology**



# Importance of Technology in Scientific Discovery

(Hypothesis: Great Tools to see lead to Great Discoveries)



Courtesy of Dr. Bruce Rosen

# Importance of Technology in Medicine and Neuroscience

PROCEEDINGS OF THE IEEE

VOLUME 94, NUMBER 4

APRIL 2006

Special Issue on:

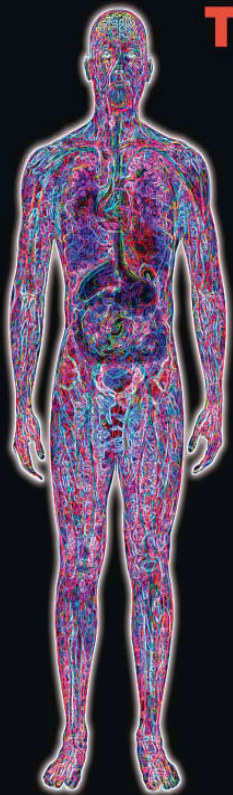## THE PHYSIOME AND BEYOND

Papers on:

Modeling Human Physiology: the IUPS/EMBS Physiome Project  
\* Handling Large-Scale Biomolecular Measurements In Silico \* Mechanical Instabilities for In Silico Analysis of Cell Dynamics  
\* Biomechanics Modeling of the Musculoskeletal Apparatus \* Kidney Modeling: Status  
\* Lung Circulation Modeling \* Computational Methods for Cardiac Electromechanics  
\* Computational Models of (Patho)Physiological Brain Activity \* Signal Processing for Short-Term Cardiovascular Interactions  
\* Multiscale Modeling of Cell-to-Organ Systems  
\* Biological Networks Analysis


plus

Scanning Our Past: Electrical Engineering Hall of Fame-Cummings C. Chesney



That our understating of the human brain has advanced more in the last two decades than in the rest of human history is a well-known fact.

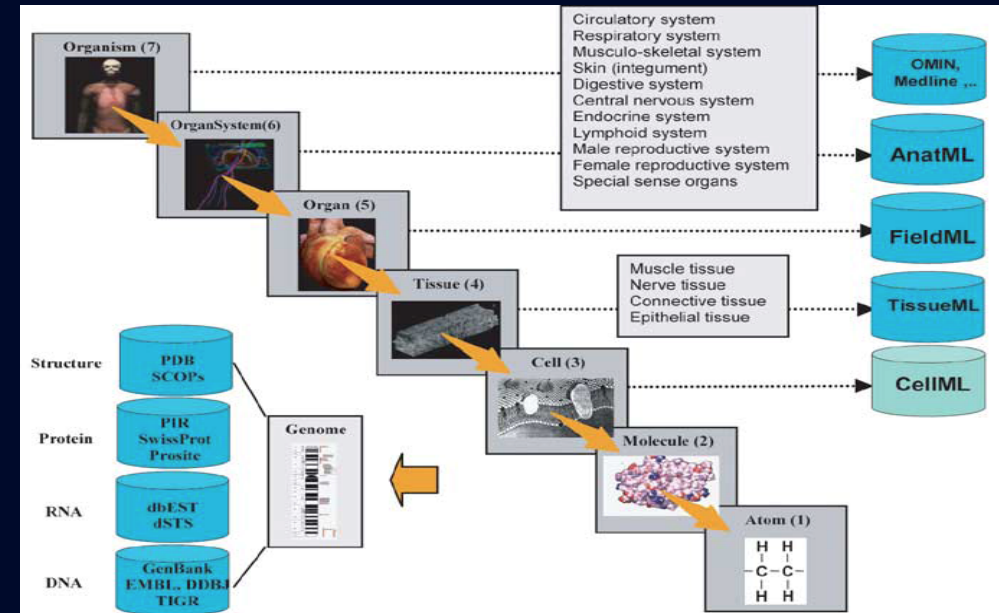
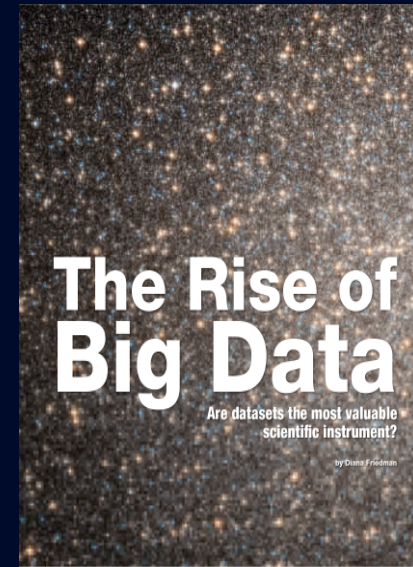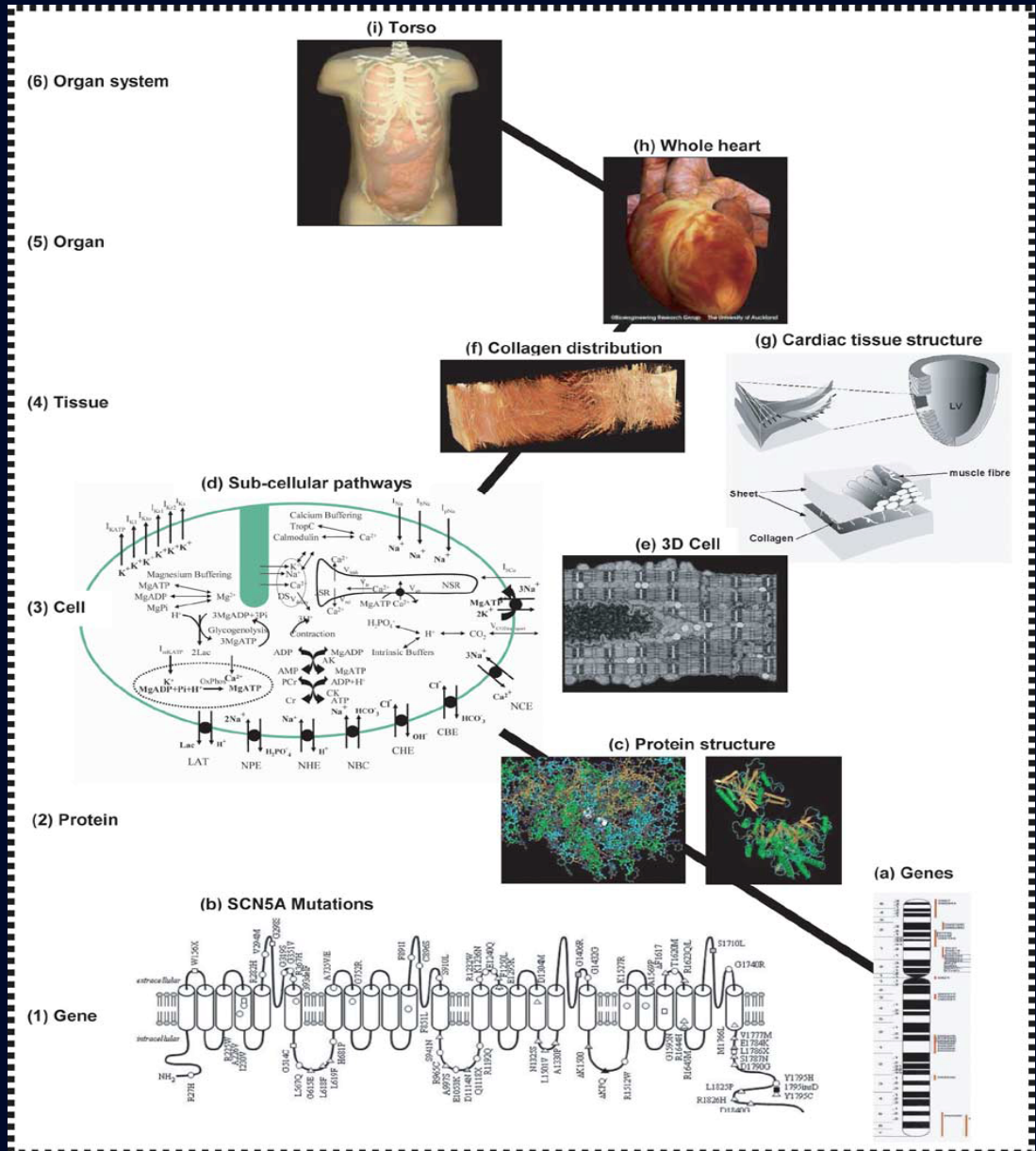
This seems to be a consequence of **key technological discoveries** as has occurred in other fields of science in the course of history.



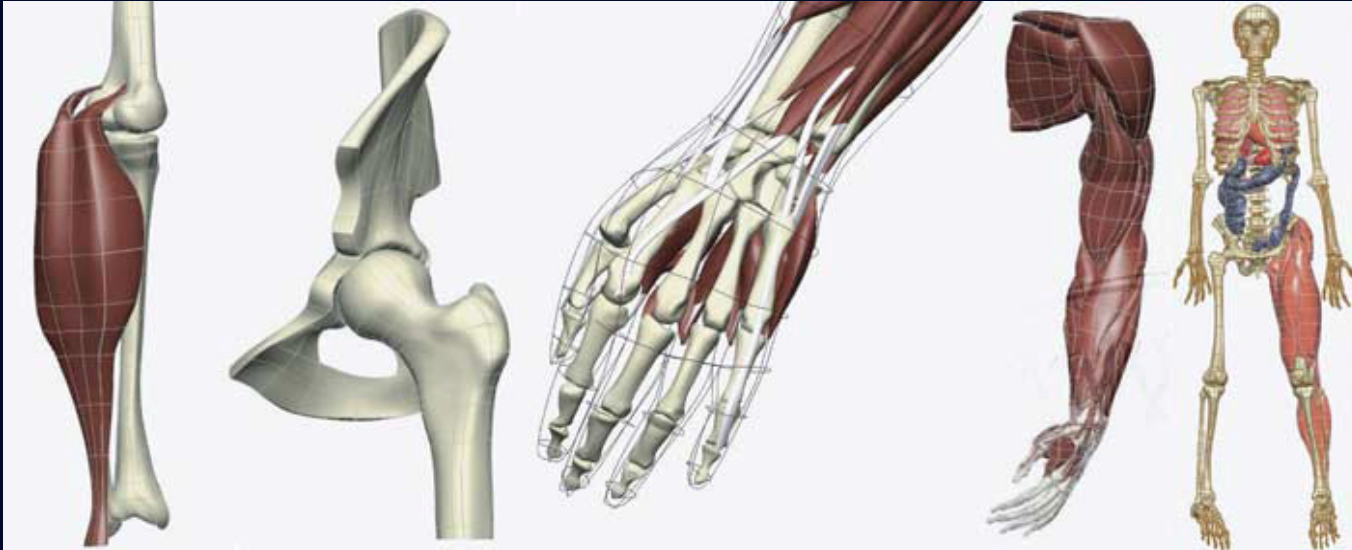
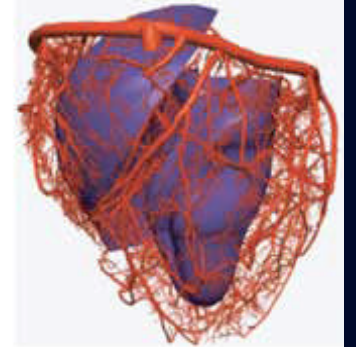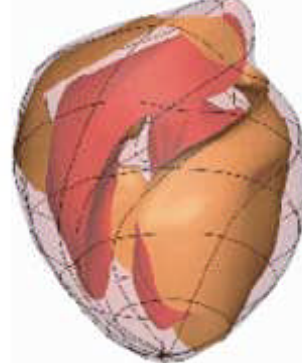
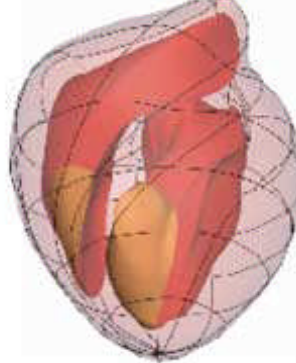
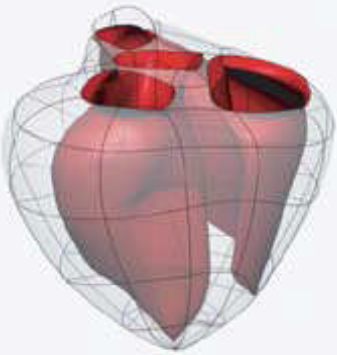
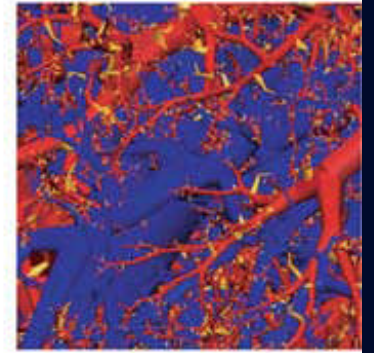
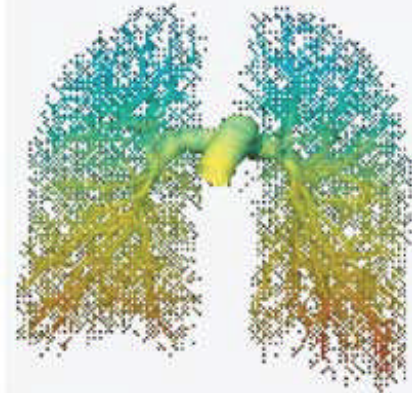
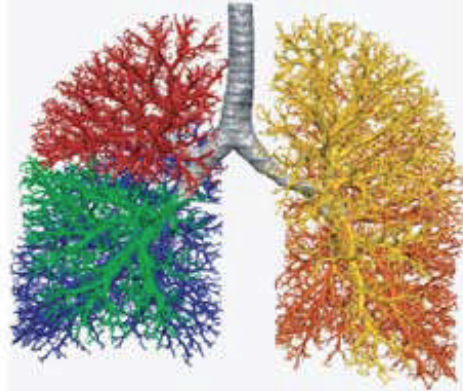
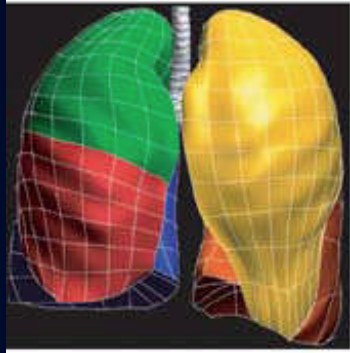
**MRI was rated by general practitioners in the USA as the principal contributor to medical practice** today over the last decade (i.e., 1991-2000) (Fuchs VR and Sox HC Jr. (2001) Physicians' Views Of The Relative Importance Of Thirty Medical Innovations, Health Affairs: Vol. 20, Number 5).

# Modeling Human Anatomy and Physiology

(Integration across multiple levels of description is a major goal in medicine)



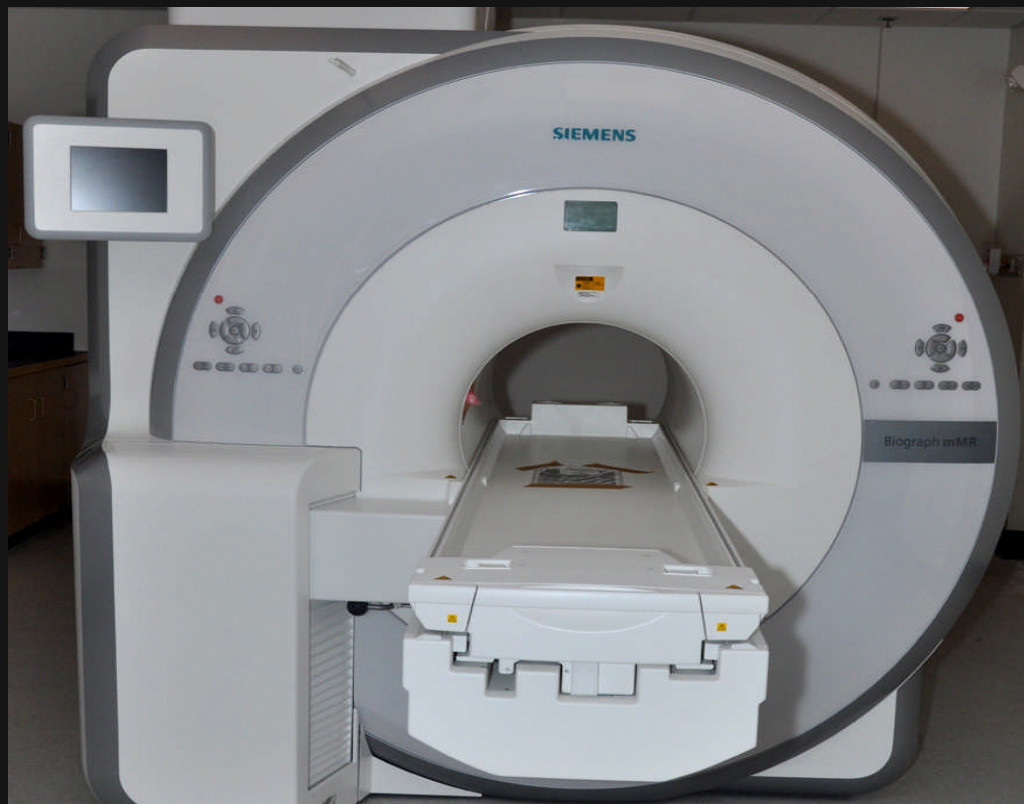



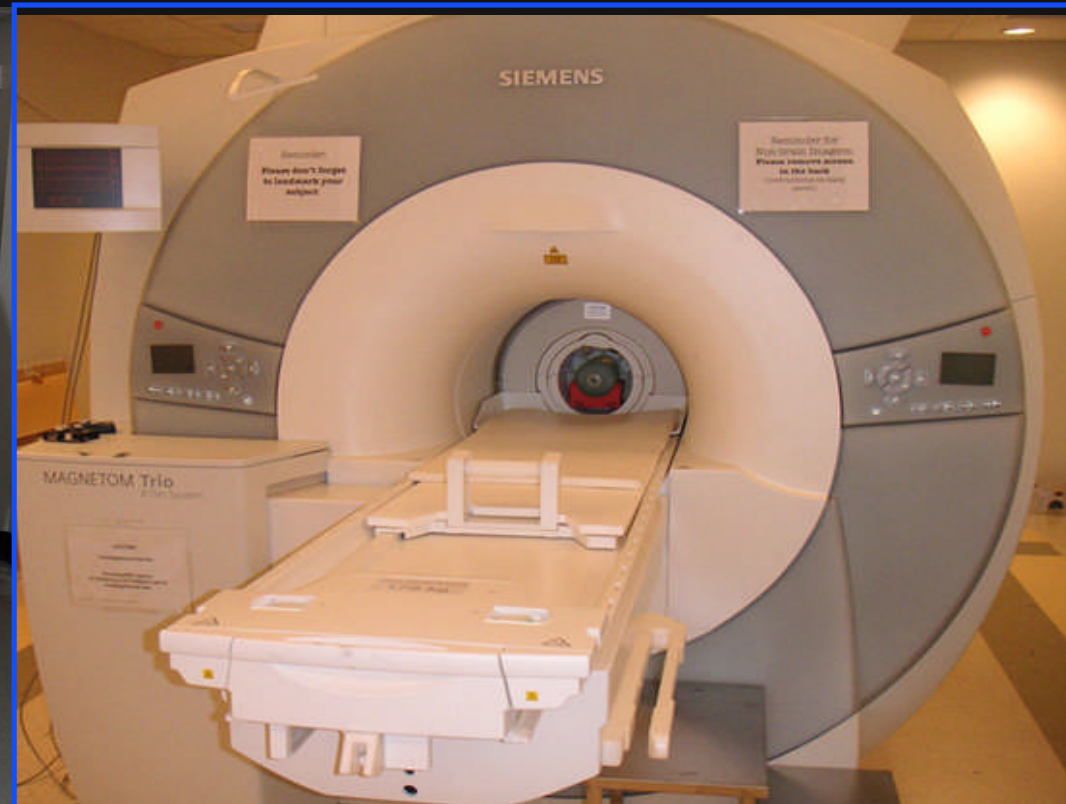
# MRI-PET installations at MGH

Unique Instruments in New England

Nuclear Imaging two ways



Whole Body



Head-only

*Importance of Technology in Neuroscience*

*Courtesy of Dr. Bruce Rosen*

# **Magnetic resonance imaging (MRI) technology had a critical role in understating the human brain.**

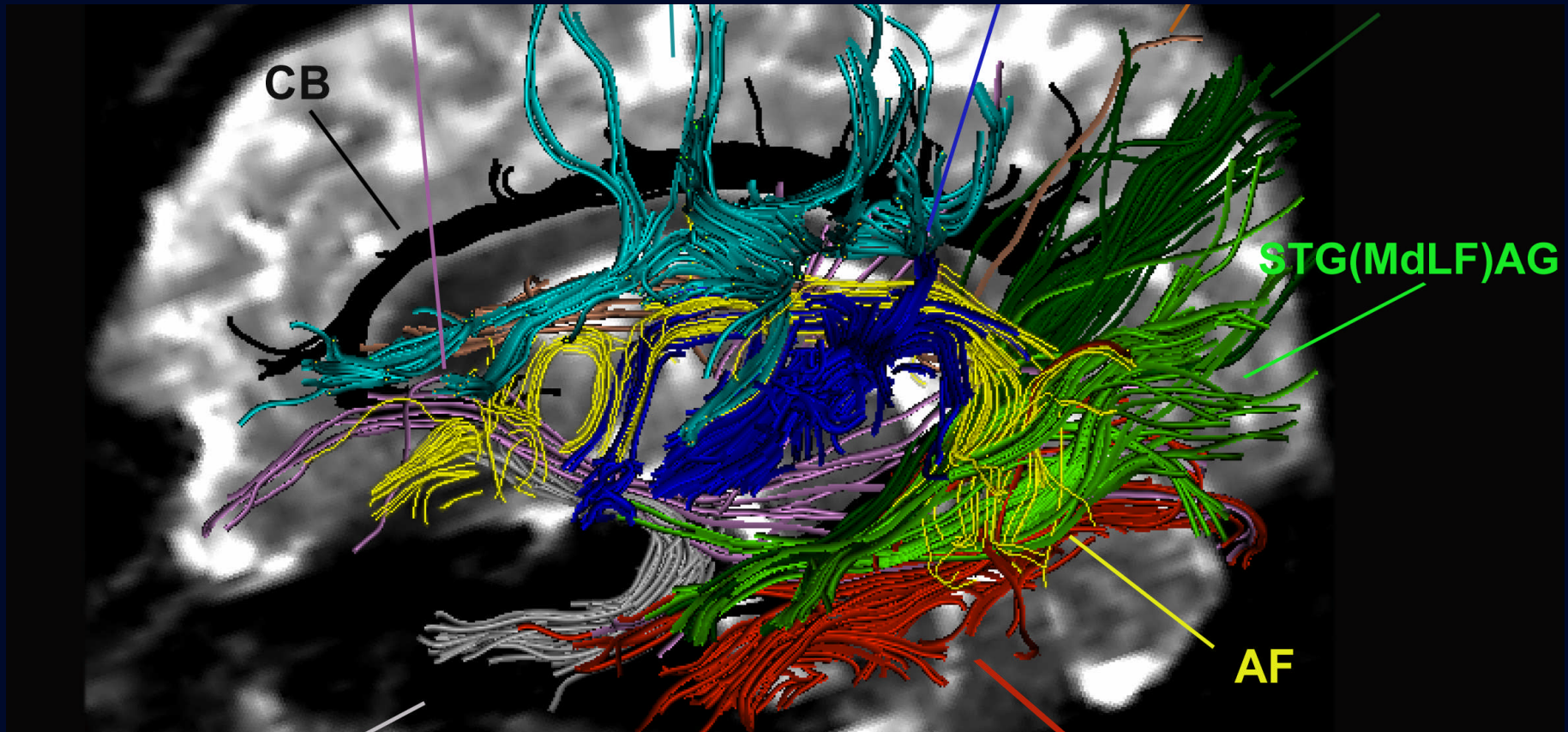
Besides the great cultural and intellectual value of the accrued information and novel conceptualizations in brain science, **these advances had a tremendous impact on the way we are currently facing neurological and psychiatric diseases and the neurosurgical approaches we adopt for diagnosis, surgical planning and treatment.**

”Despite 4000 papers, not a single finding has changed routine clinical care in psychiatry”


But this will change, and the change will revolve around a new definition of psychiatric diseases as disorders of brain *circuitry* - that this will change our definition of the illnesses, and “our understanding of their causes, treatments, and preventions”

Paraphrasing Tom Insel, Director, National Institute of Mental Health

# In Imaging Research, Brain Connectivity is done with Diffusion MRI




*In astronomy, the way to sensitivity and resolution is mirror diameter*



*Corning 200" mirror for the Hale Telescope at Mt Palomar*

# Human Connectome Project



$G_{max} = 300\text{mT/m}$   
(7x Greater than conventional)

1.5 Ton gradient  
24 MWatts peak power

In *Diffusion* MRI, the way to see micro-structure is *gradient* strength

*Courtesy of Dr. Bruce Rosen*

About

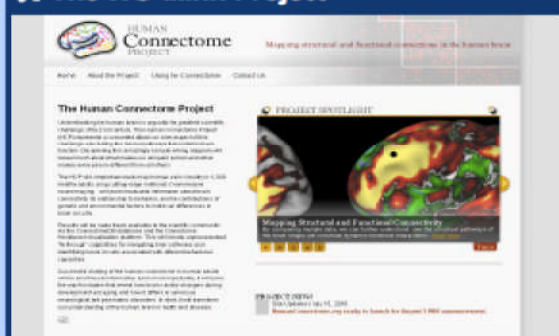The NIH Human Connectome Project is an ambitious effort to map the neural pathways that underlie human brain function. The overarching purpose of the Project is to acquire and share data about the structural and functional connectivity of the human brain. It will greatly advance the capabilities for imaging and analyzing brain connections, resulting in improved sensitivity, resolution, and utility, thereby accelerating progress in the emerging field of human connectomics.

Altogether, the Human Connectome Project will lead to major advances in our understanding of what makes us uniquely human and will set the stage for future studies of abnormal brain circuits in many neurological and psychiatric disorders.

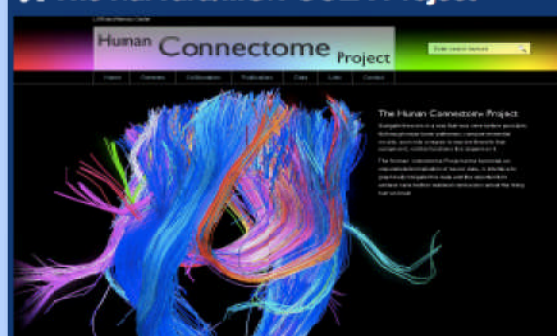
Consortia

The sixteen institutes and centers of the [NIH Blueprint for Neuroscience](#) have funded two major grants that will take complementary approaches to deciphering the brain's amazingly complex wiring diagram.

The WU-Minn Project



The Harvard/MGH-UCLA Project



Search the HCP

Search   x  
powered by Google™

HCP In The News

[Sporns' 'Networks of the Brain': a roadmap to new Indiana University](#)

The first of these projects is to develop a "virtual brain," a powerful computational model that can simulate brain function; and the second is called the Human Connectome Project, established to map the human brain's major connections. ...

[Data Overload: Scientists Struggle to Streamline LiveScience.com](#)

The goal of the Human Connectome Project (HCP), for instance, is to map connections among neurons using evidence from brain-imaging studies and link the findings to behavioral tests and DNA samples from more than 1000 healthy adults. ...

[Proposal unveiled for revamped Gateway Arch park Reuters](#)

No specifics were presented for how the money would be raised, but Walter Metcalf, an official of the foundation planning the project, said the cost would be \$578.5 million. He said funding was in the "early stage" but would use federal, ...

[Apple σημαίνει καινοτομία](#)

SigmaLive  
Το προηγούμενο έτος τα εργαστήρια της εταιρείας κατέθεσαν 2.537 αιτήσεις διπλωμάτων ευρεσιτεχνίας, ενώ στα νέα της εγχειρήματα συγκαταλέγεται το Human Connectome Project, μια απόπειρα να χαρτογραφηθούν οι συνδέσεις του ανθρώπινου εγκεφάλου. ...

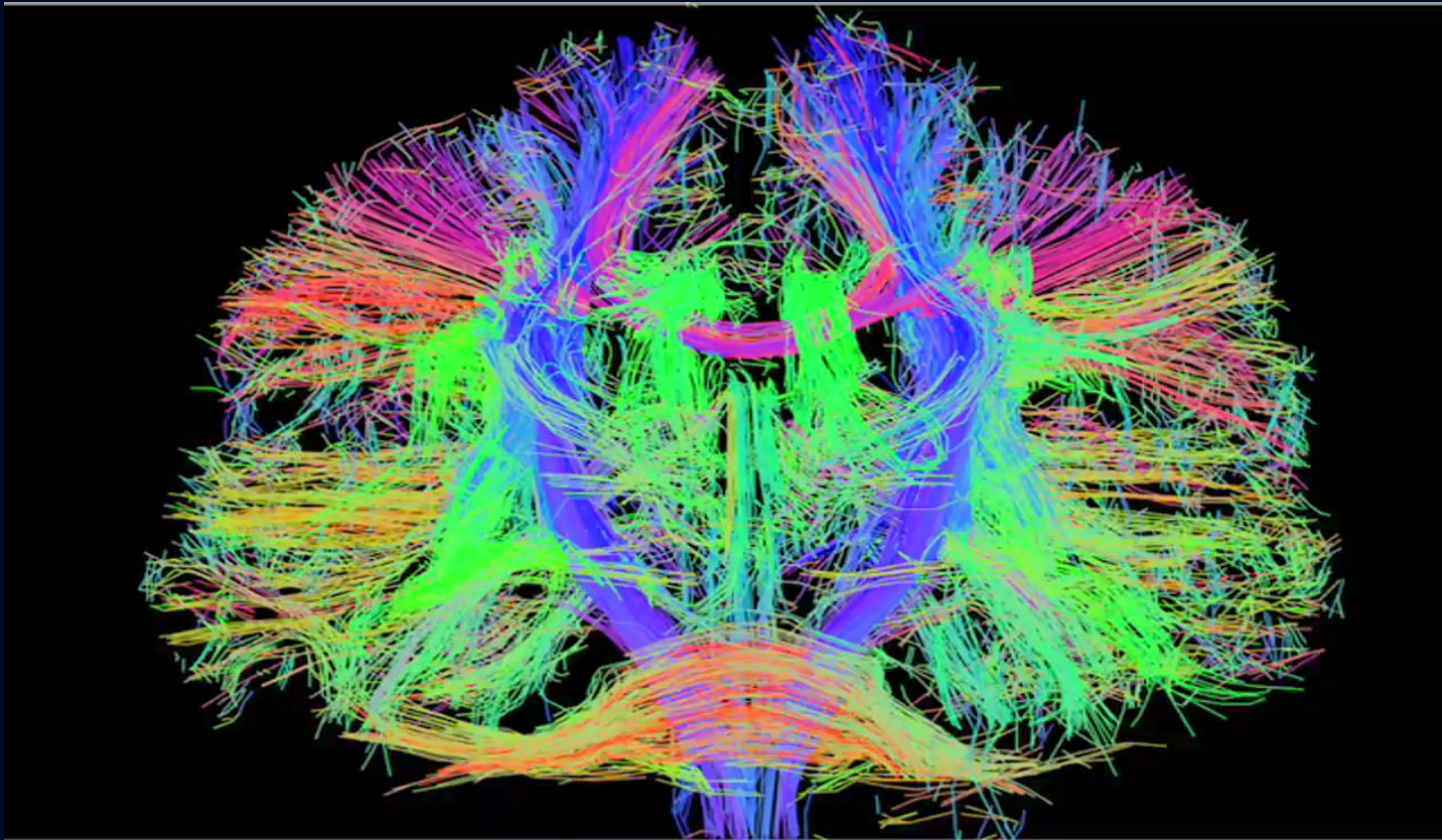
powered by Google™

NIH HCP Initiative History

- Human Connectome Project grant published July 15, 2009. (RFA, [Press Release](#))



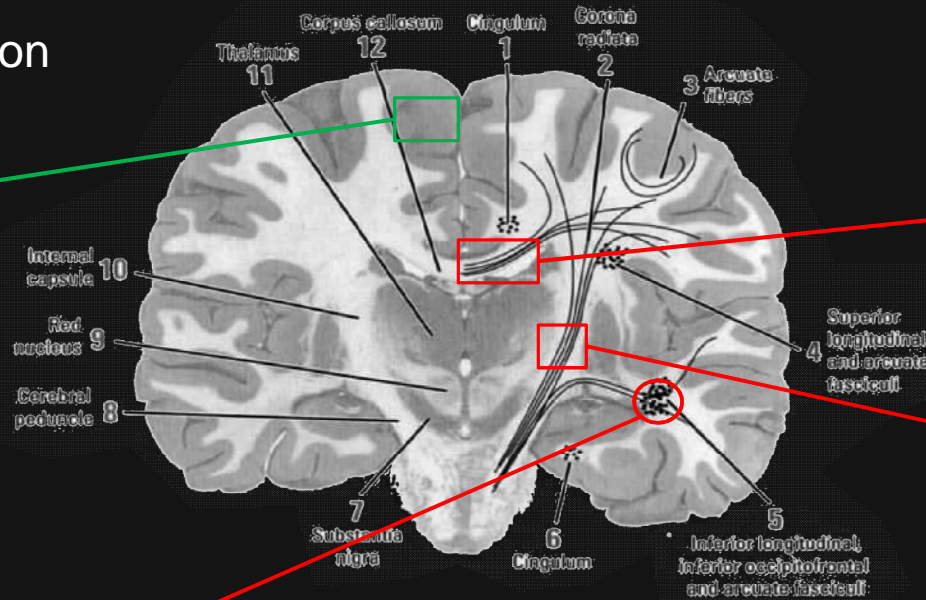

# Diffusion Imaging of Microstructure



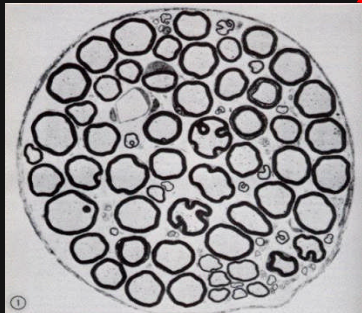
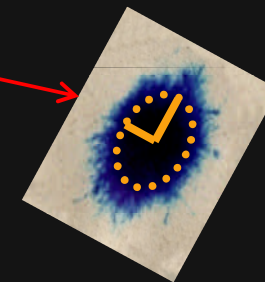

*Courtesy of Dr. Bruce Rosen*

# Water Diffusion in the Brain has *Directionality*

*Isotropic* diffusion




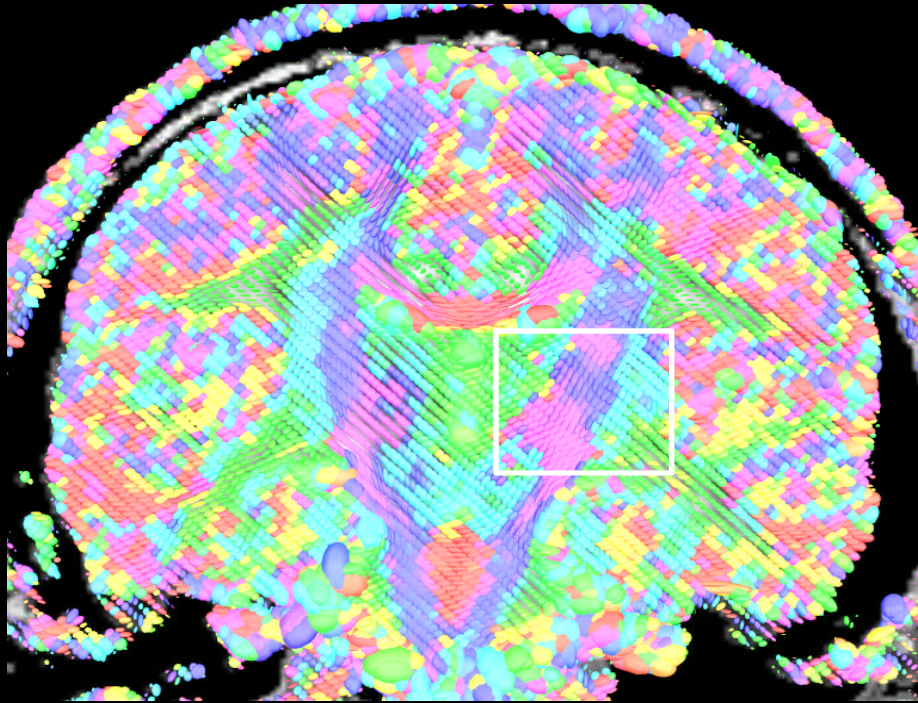
*Anisotropic* diffusion



Possible sources of anisotropy:

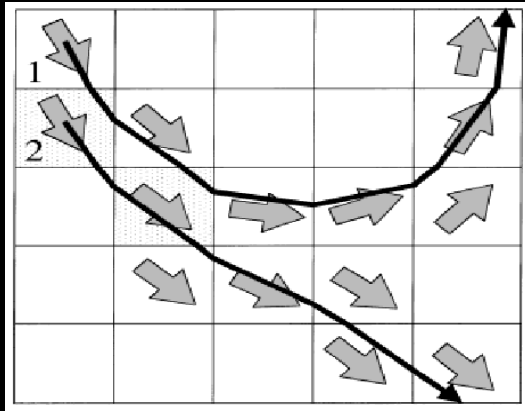
- Axonal membranes of *densely packed axons hinder diffusion* perpendicularly to the fiber long axis.
- Myelin may also modulate anisotropy.

# Diffusion Tensor Imaging

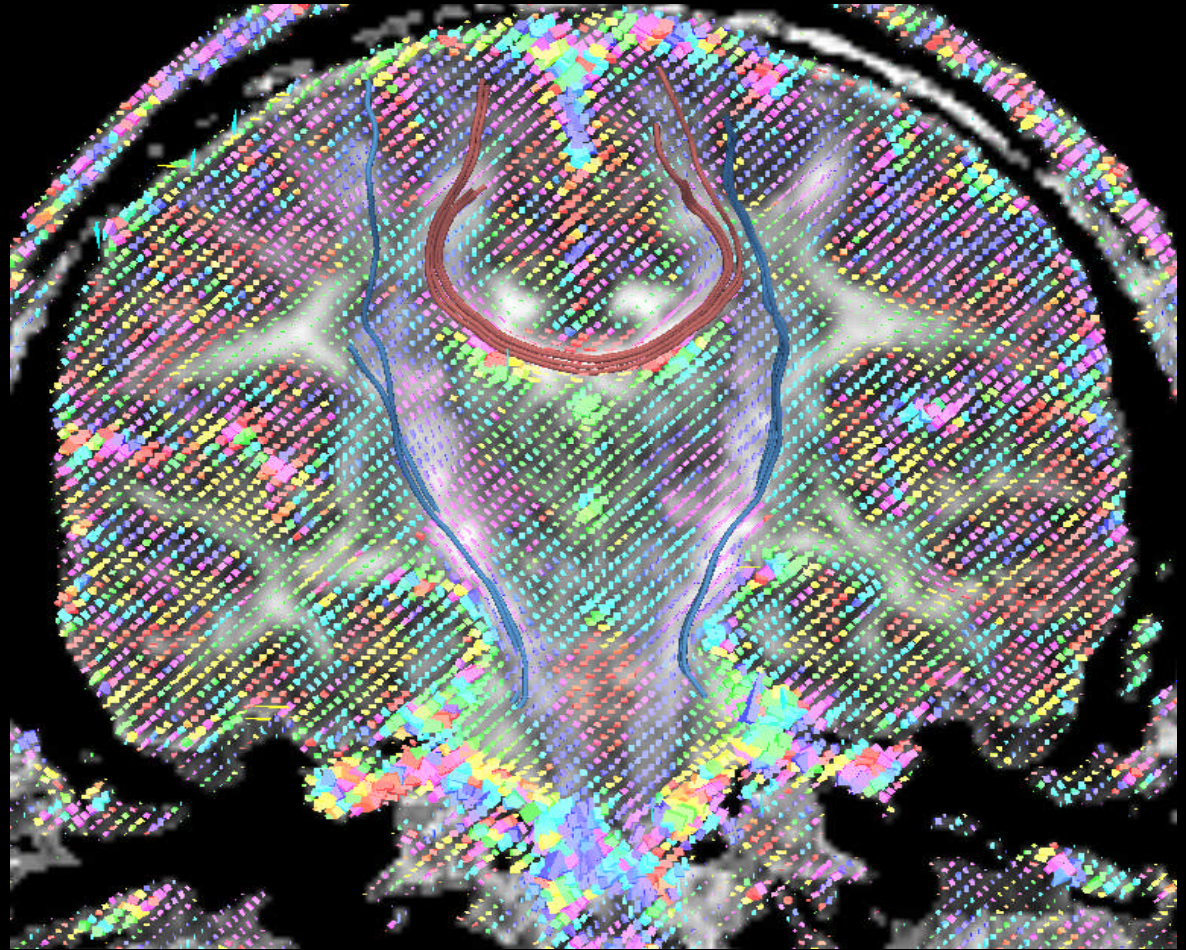


- At each location, the diffusion behavior of water is modeled as an ellipsoid.
- In medical imaging this ellipsoid is called a **diffusion tensor**.

# From Tensors to Tracts

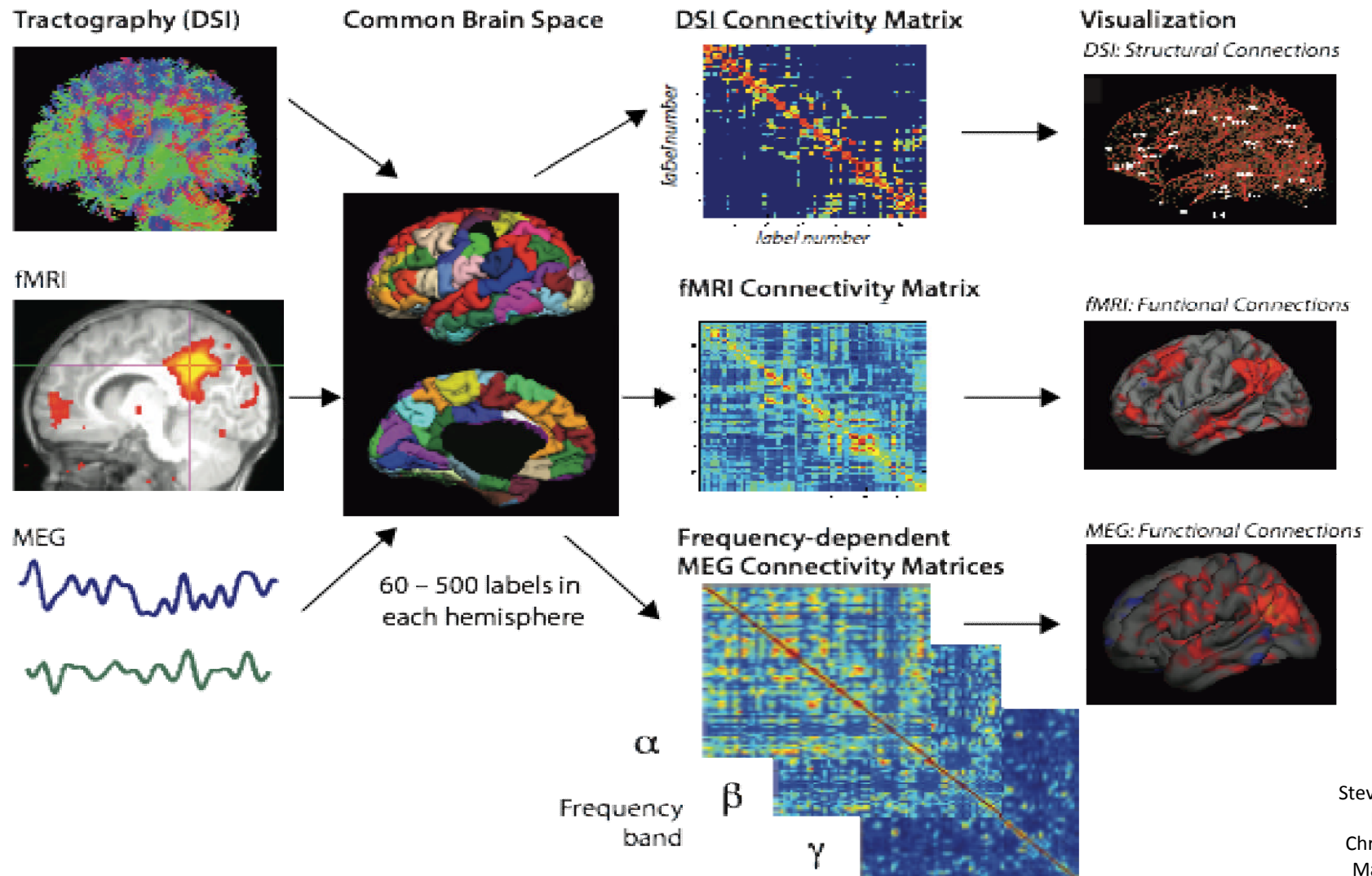


- Associate the major diffusion direction with the tangent to a curve.
- Estimate the curve from its tangents.



# Multimodal Brain Connectivity

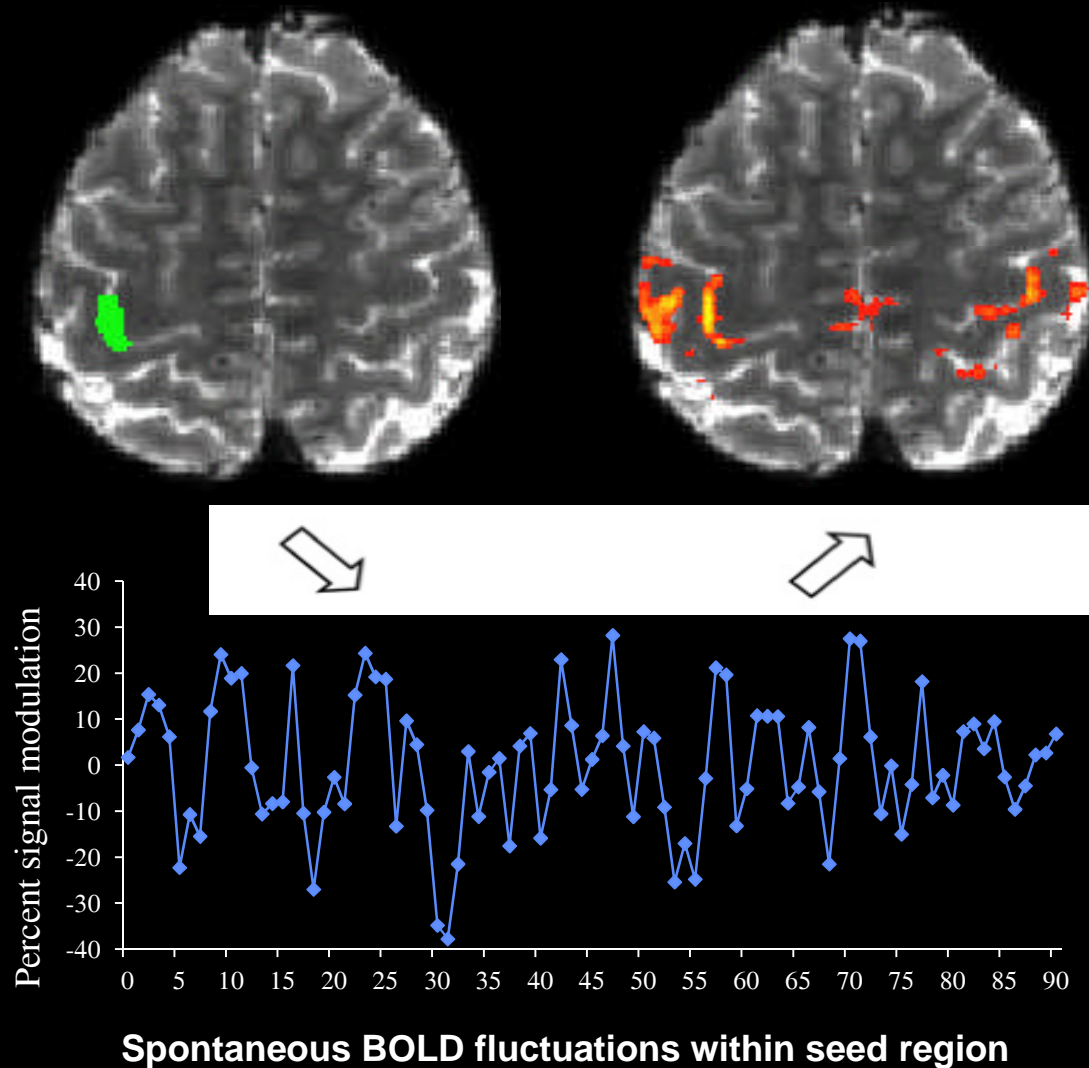
*Resting State Correlations Approach: DSI, fMRI, MEG Connections in a Common Brain Space*

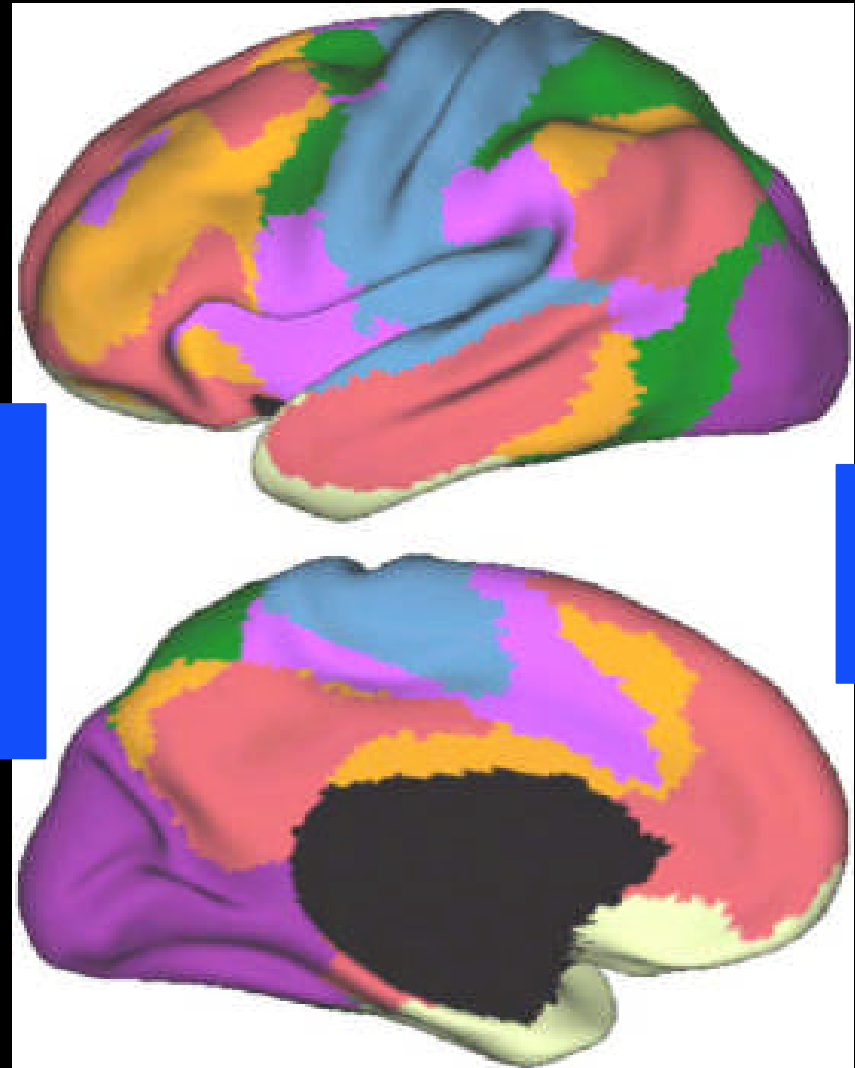
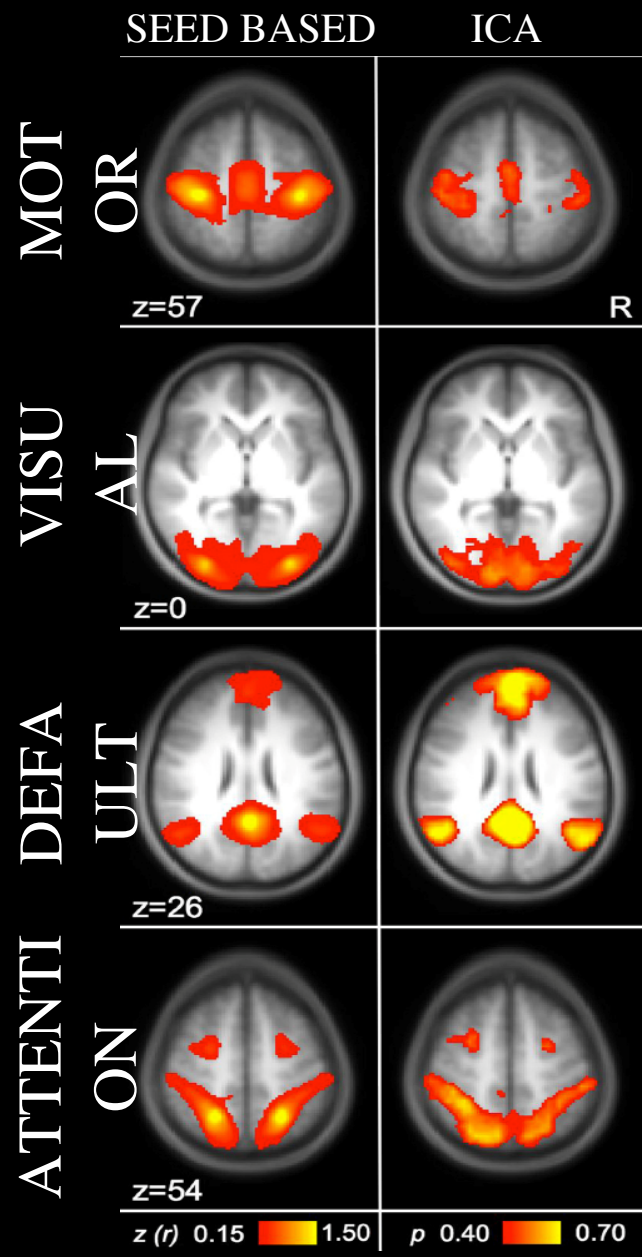


Courtesy of:  
Steven Stufflebeam  
Patric Hagmann  
Christopher Honey  
Matti Hämäläinen

How does assessment of large neuronal circuits using functional connectivity MRI work?

**While people are simply resting, the brain shows large, spontaneous, activity fluctuations**

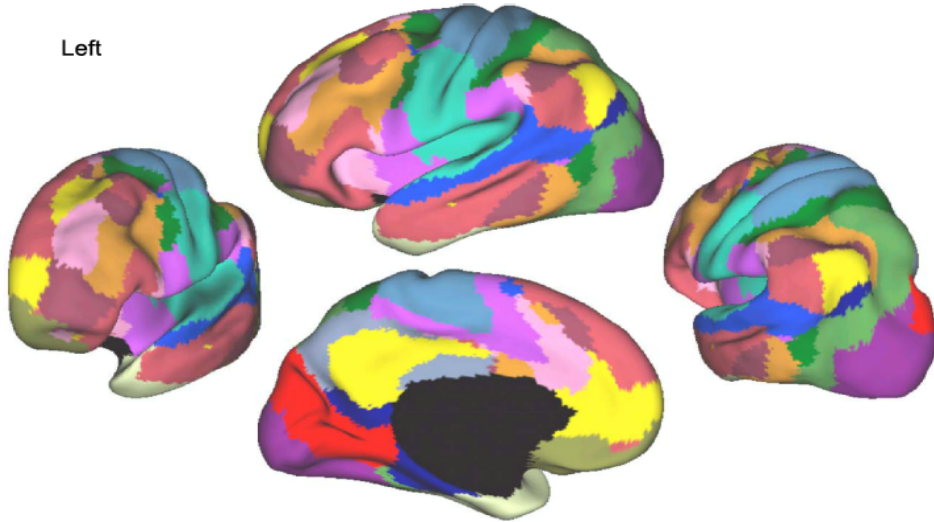






17-Network Parcellation (N=1000)

Left



Right

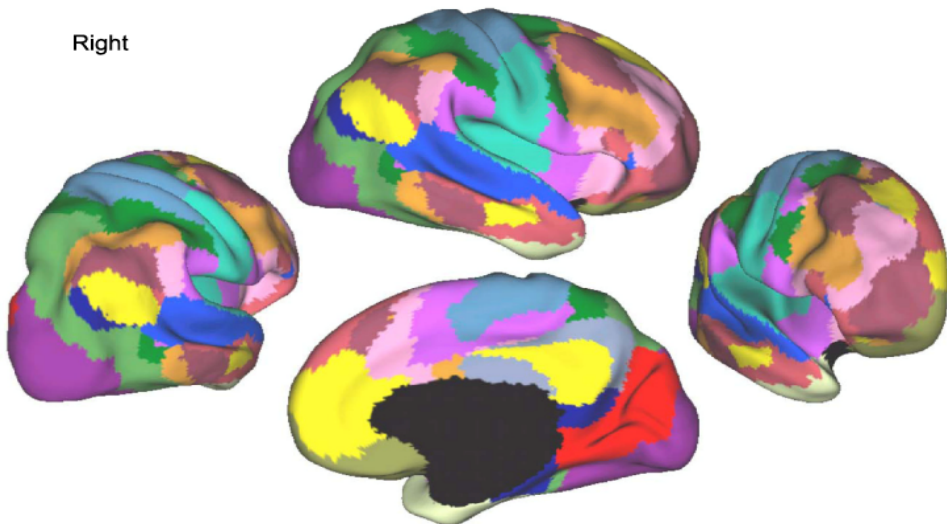
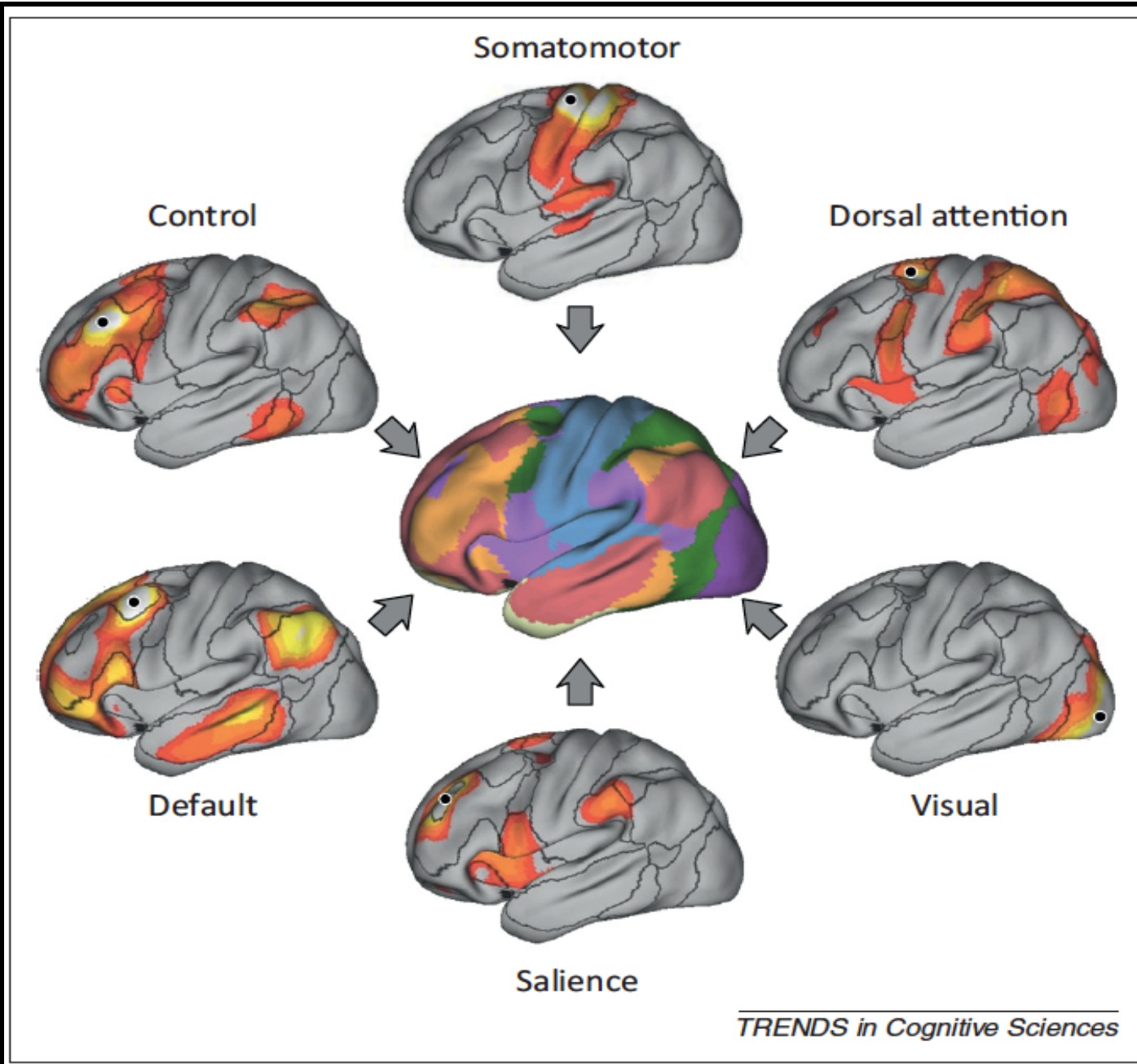
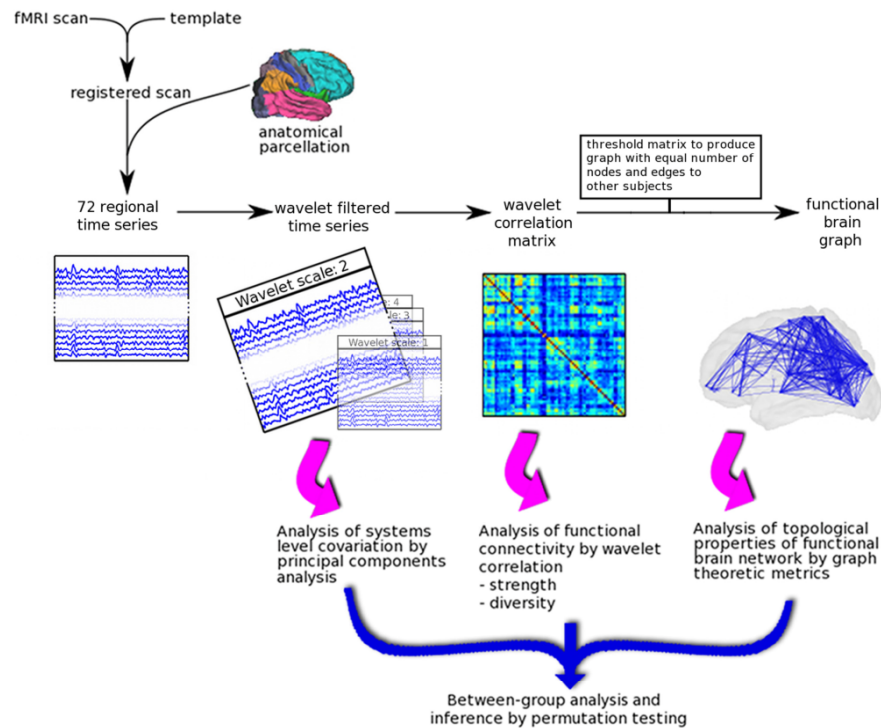


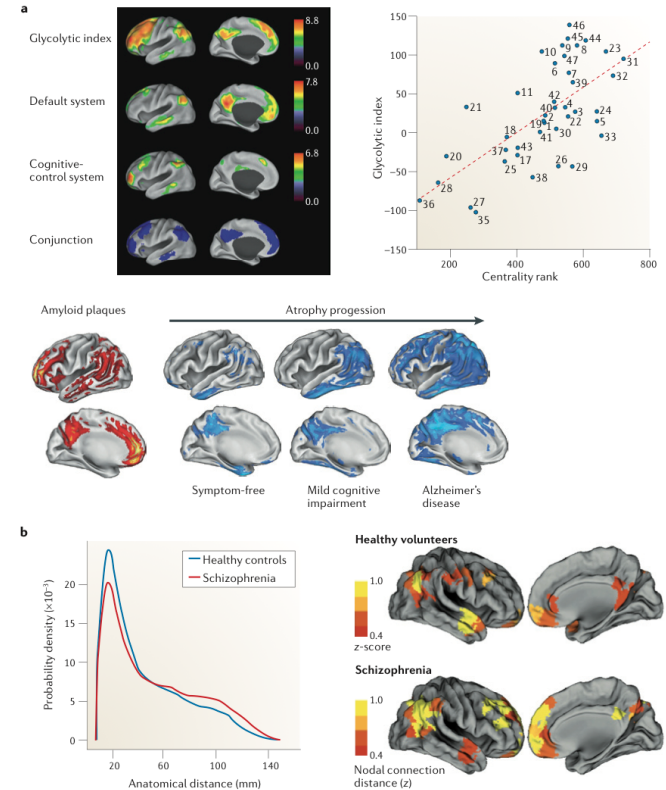
Fig. 13. A fine-resolution (17-network) parcellation of the human cerebral cortex based on 1,000 subjects. To provide the best estimates of the 17 cortical networks, clustering was performed on the fMRI data of the full 1,000 subjects. The 17-network estimate fractionated the 7-network into smaller networks. Some aspects of the fractionations have been previously noted in other studies.





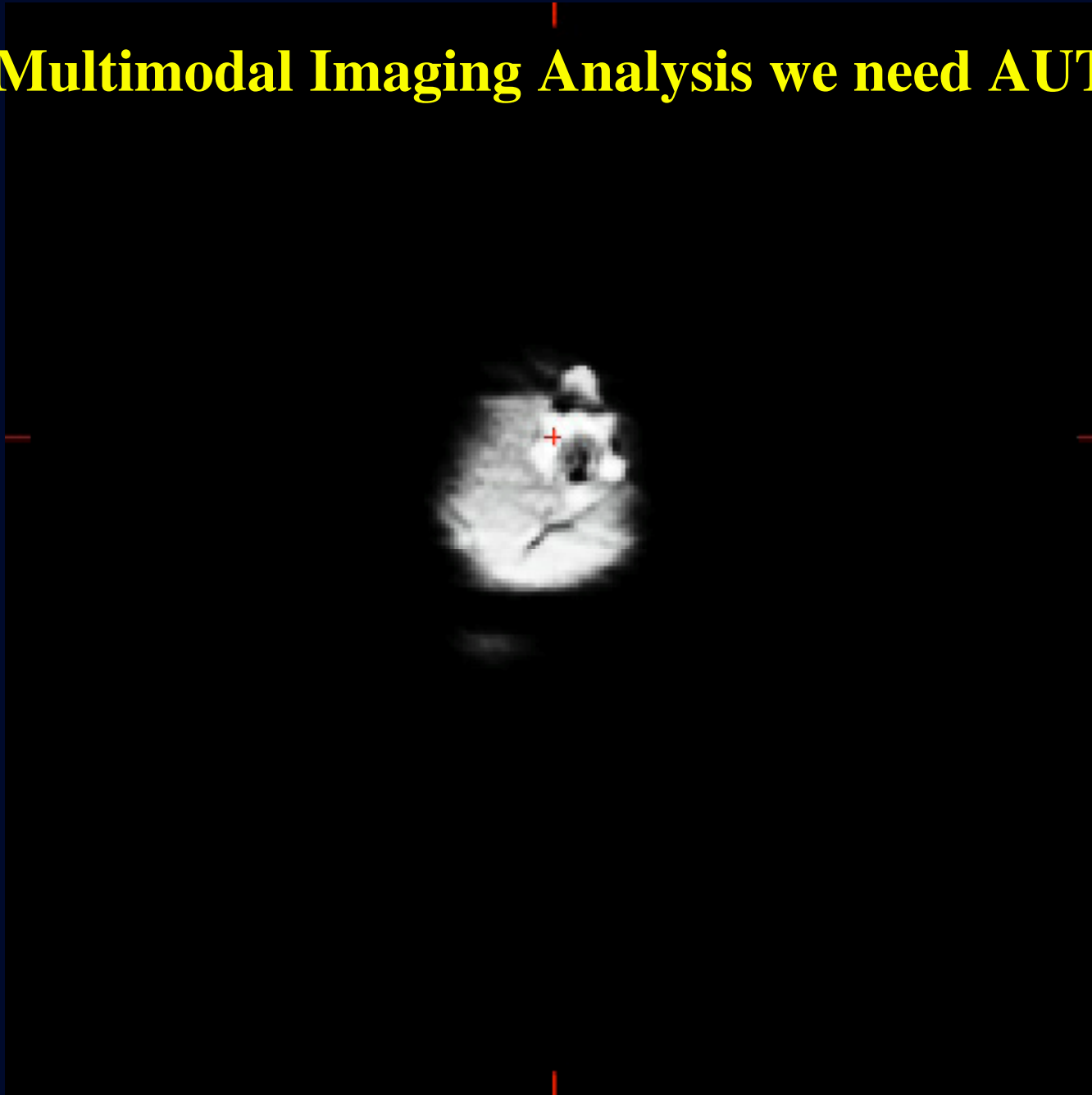
**Figure 1.** Schematic of fMRI data analysis pipeline. Regional mean fMRI time series were estimated by applying a prior anatomical template image to each individual fMRI dataset after its coregistration with the template in standard space; wavelet analysis was used to bandpass filter the regional time series and to estimate frequency-specific measures of functional connectivity between regions; functional connectivity matrices were thresholded to generate binary undirected graphs or brain functional networks; between-group differences in functional connectivity, principal components, and network topological metrics were assessed by permutation testing.

## REVIEWS

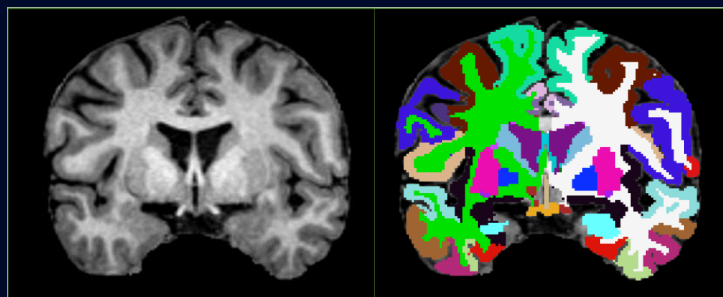


**Figure 4 | Brain disorders affect high-cost components of networks.** **a** | Brain networks and brain metabolism. The top left panel shows the regional distribution of aerobic glycolysis (as measured using the glycolytic index), the default mode system and the cognitive control system (as mapped by resting-state functional MRI (fMRI)) and the conjunction of these two systems with the glycolytic index, illustrating their overlap<sup>161</sup>. The top right panel shows a scatter plot of the centrality rank (which is estimated from the betweenness centrality of the connectomes of five participants<sup>41</sup>) and the glycolytic index<sup>161</sup> for 41 Brodmann areas of the cerebral cortex. The correlation is highly significant, with  $r = 0.66$  ( $P < 0.00005$ ), indicating that areas with high centrality — that is, the structural hubs — have a high glycolytic index<sup>64,161</sup>. Several of these hub nodes are members of the default and cognitive control systems. The bottom panel shows that high-cost hub nodes (including regions comprising the default mode system and the cognitive control system; see top left panel) are typically first affected by amyloid deposition and grey-matter atrophy in Alzheimer's disease, leading to disruption of memory functions that are dependent on large-scale network integrity<sup>162,163</sup>. **b** | fMRI networks in patients with schizophrenia contain proportionally more long-distance connections than fMRI networks in healthy controls (left panel), perhaps owing to excessive developmental pruning of shorter-distance connections. Accordingly, inter-modular connector hubs that have a large number of long-distance connections (indicated by areas with high connection distance in the right panel) are more extensive in functional brain networks of people with schizophrenia than in healthy volunteers<sup>45</sup>. Part **a** is reproduced, with permission, from REF. 161 © (2010) National Academy of Sciences, and from REF. 163 © (2008) New York Academy of Sciences. Part **b** is reproduced, with permission, from REF. 46 © (2012) Oxford Journals.

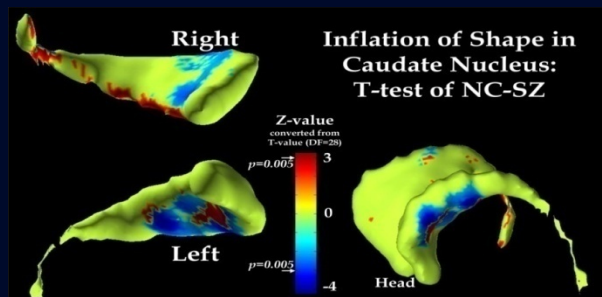
**For Multimodal Imaging Analysis we need AUTOMATION**



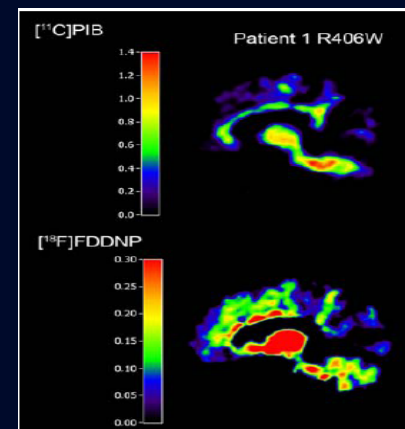
# Methodologies



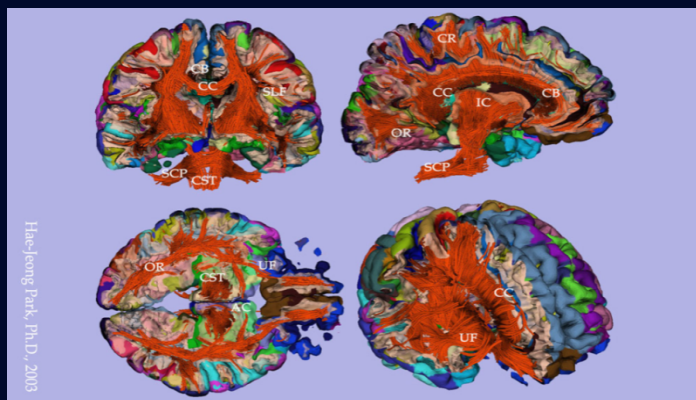
Volume - Morphometry



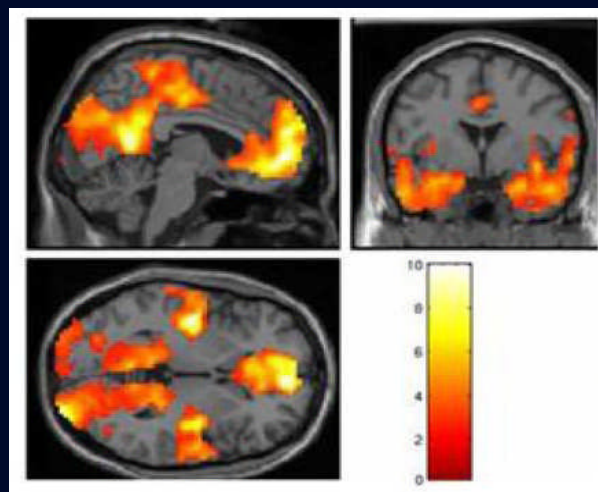
Shape - Morphometry



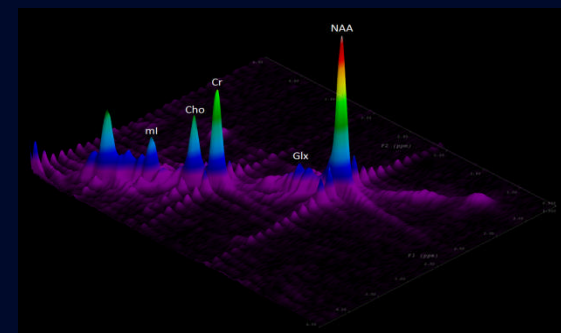
PET



Diffusion Imaging



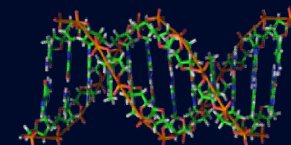
Functional Imaging



MR Spectroscopy

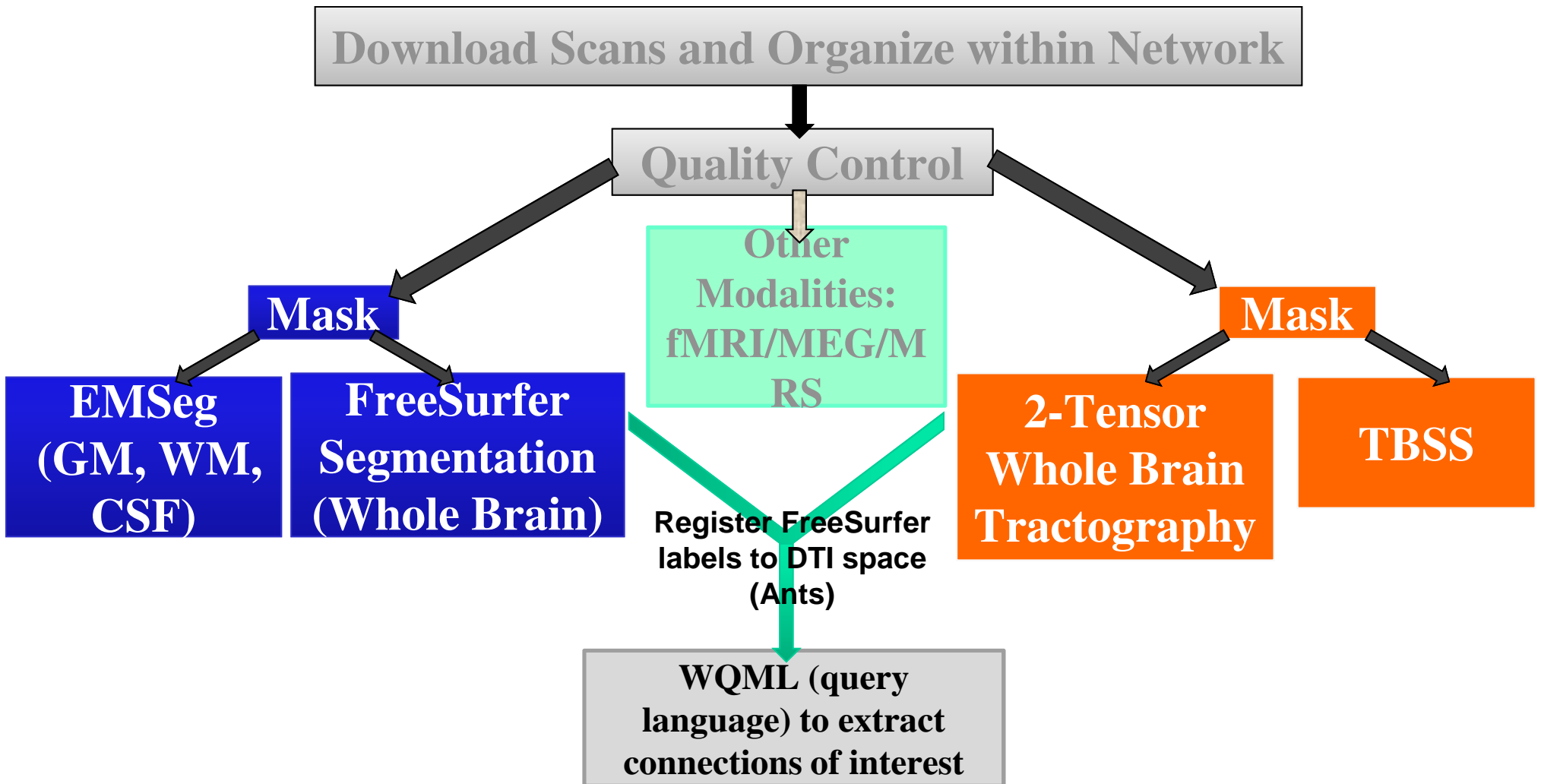


Data Infrastructure



Genetics

# PNL Pipeline



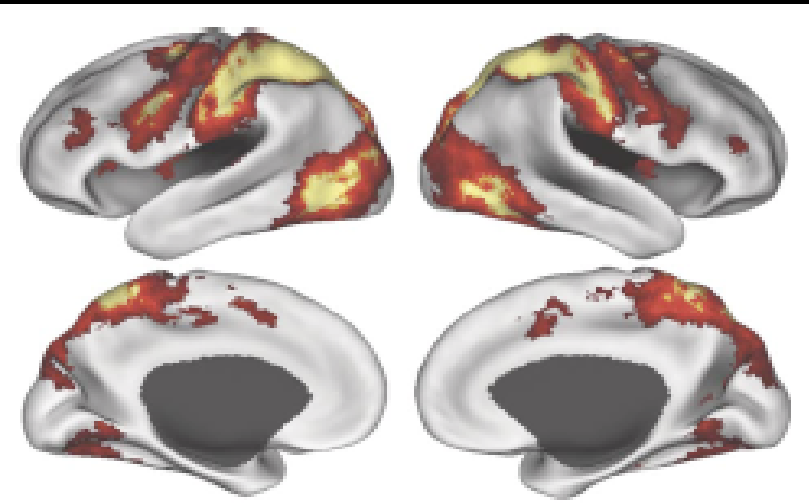
As methodologies seem to have limitations, these should be known thoroughly to be able to use any given technique optimally and efficiently

*“A real man knows his limits” Clint Eastwood*

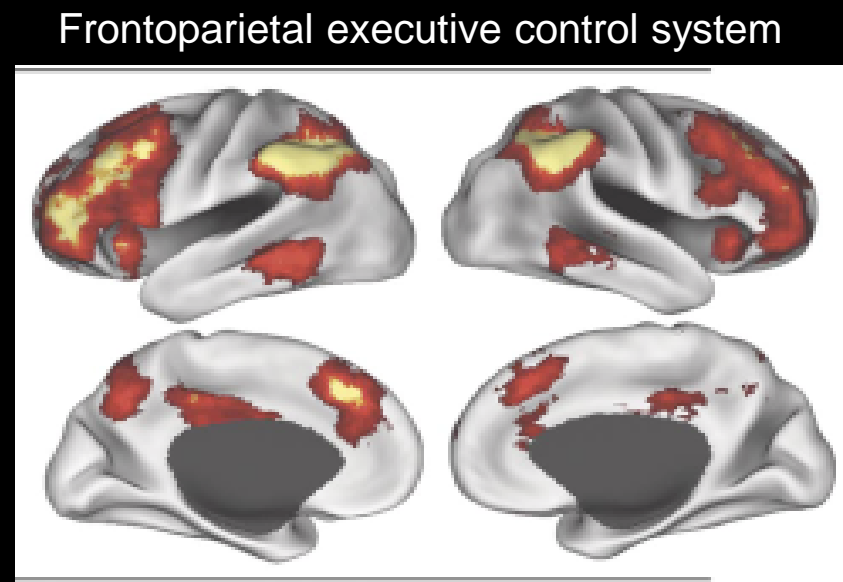
# Imaging Brain Circuitries in Basic and Clinical Neuroscience



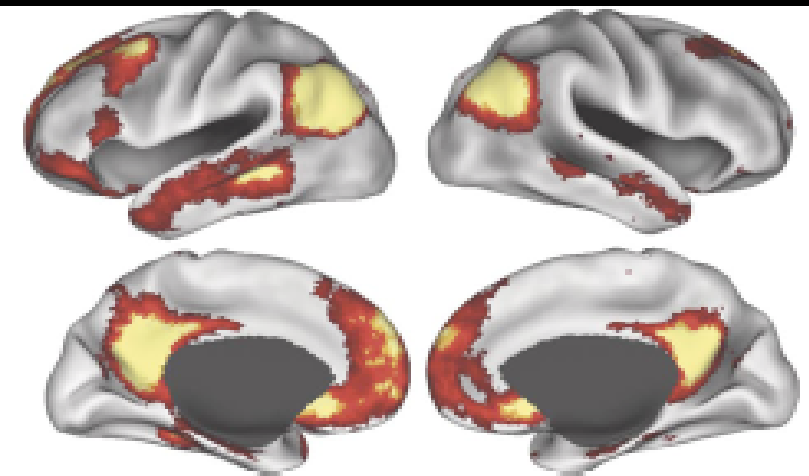
# Large-scale cognitive systems understood through resting state fMRI



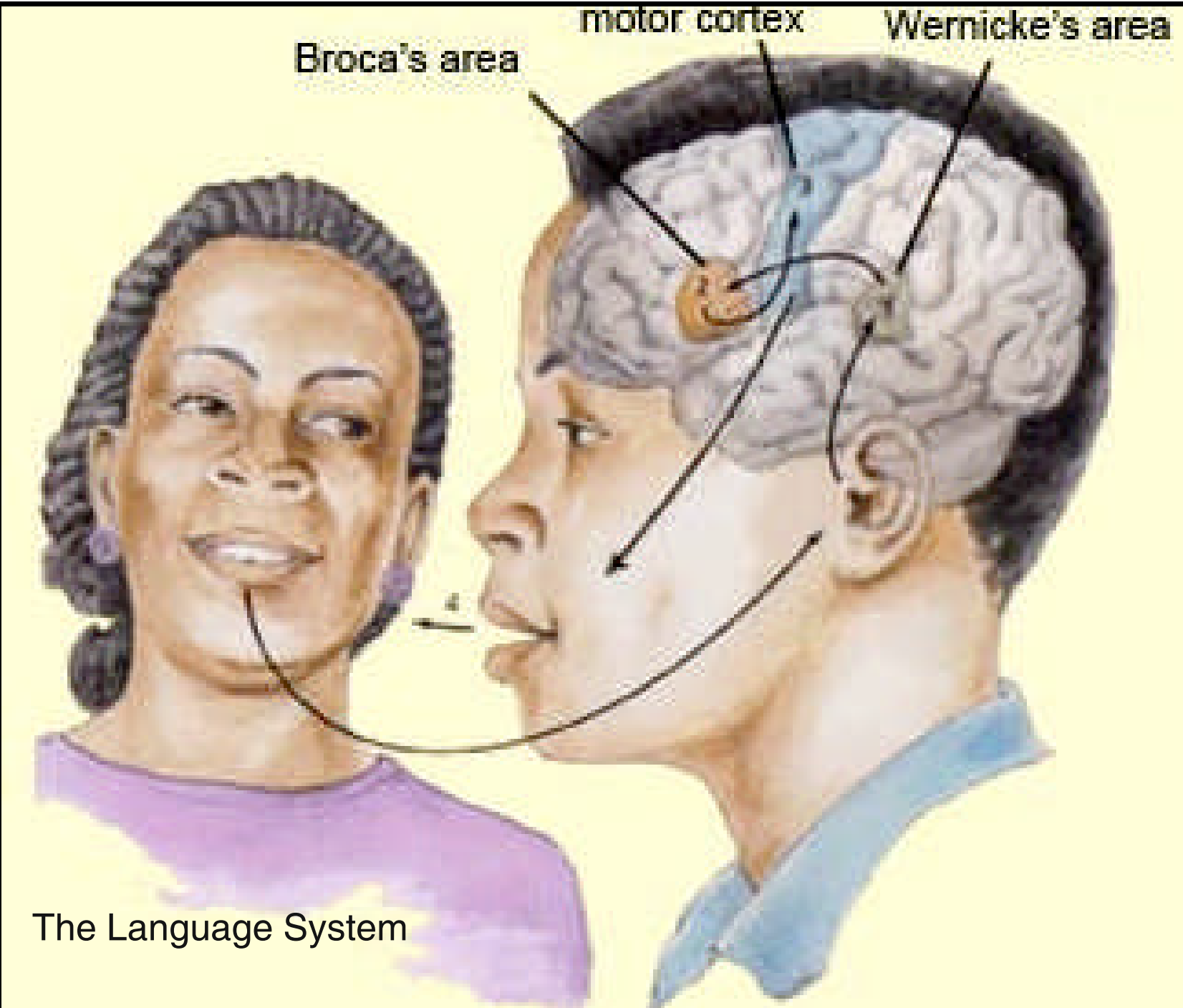
Dorsal visuospatial attention system



Frontoparietal executive control system

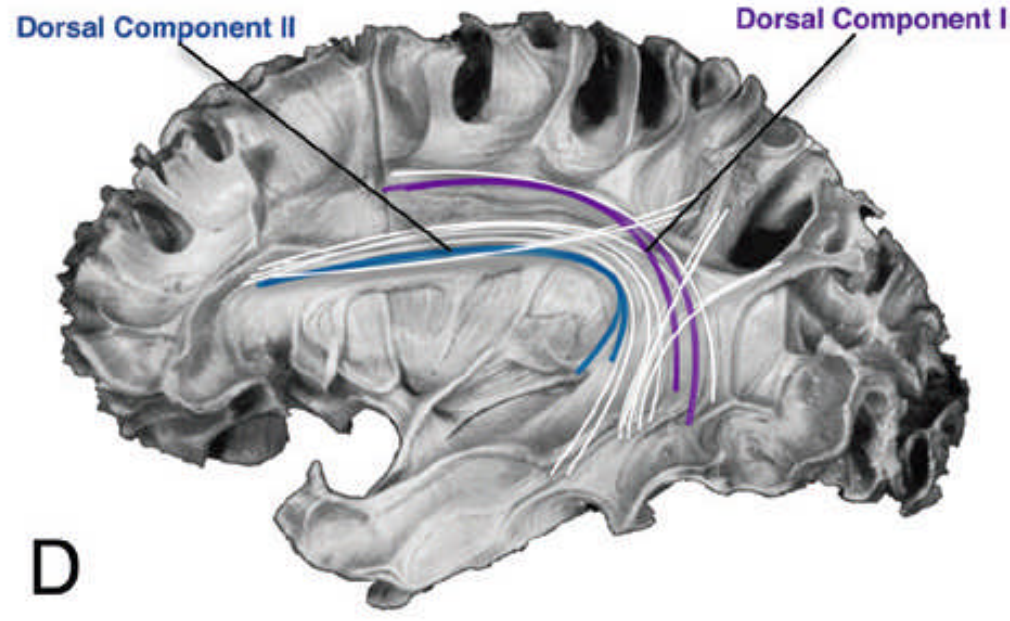
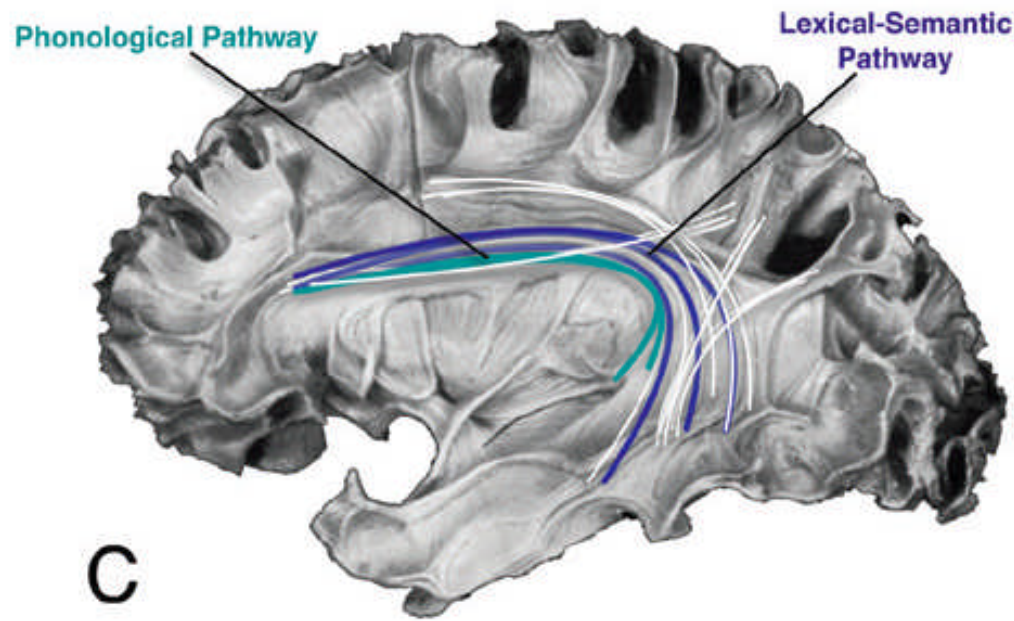
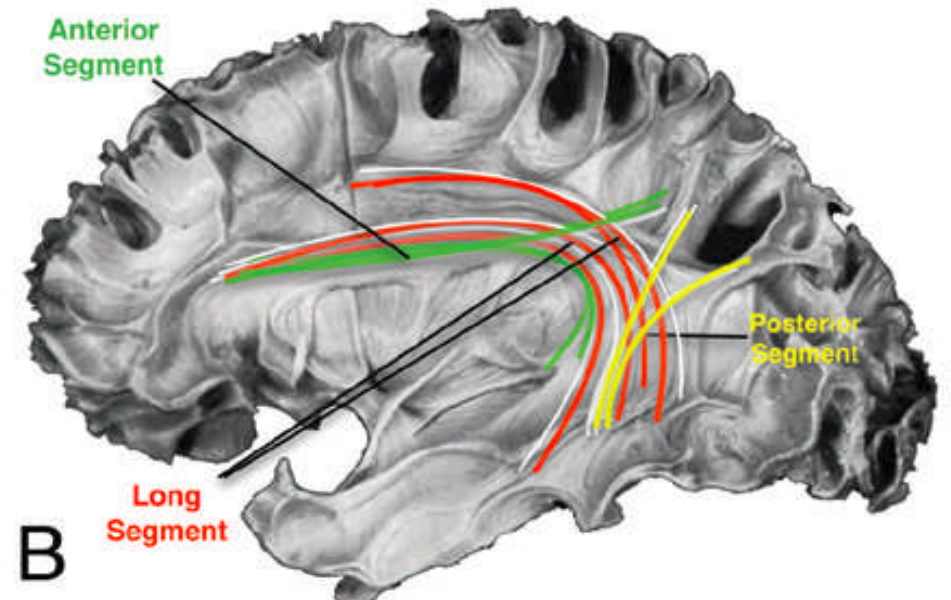
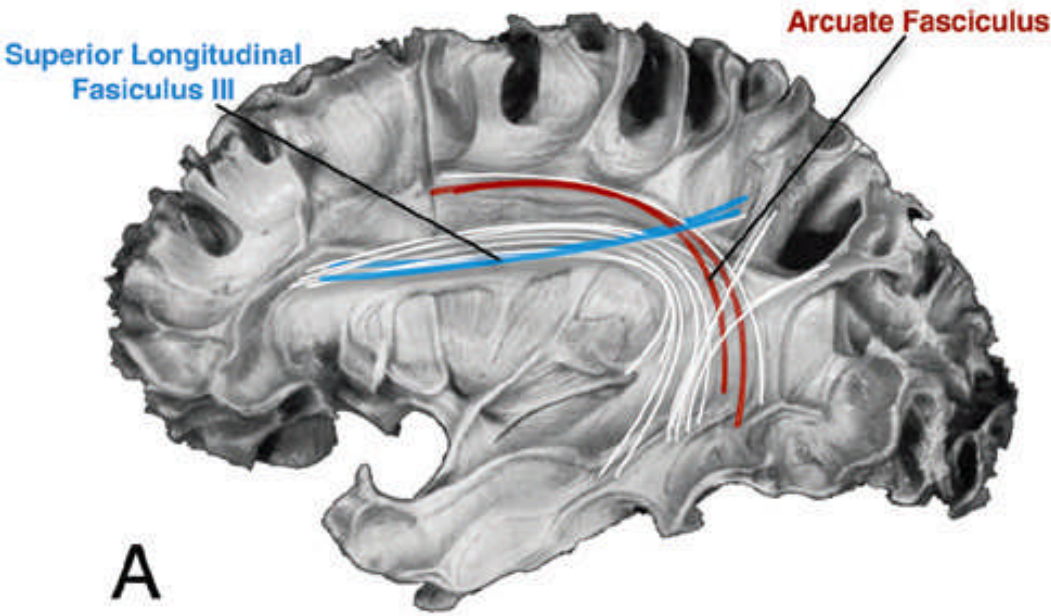


Episodic memory/Default-mode system

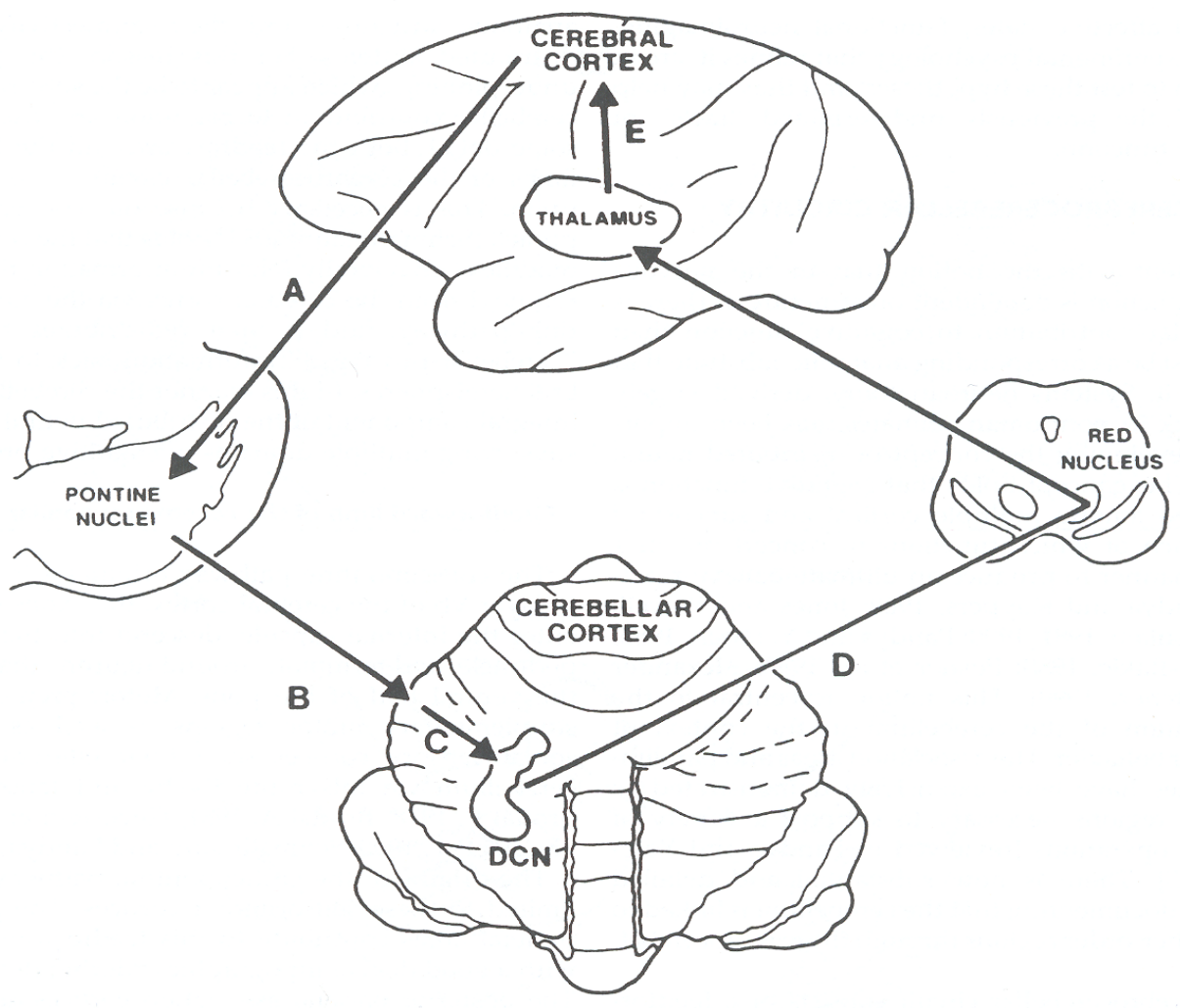


The Language System

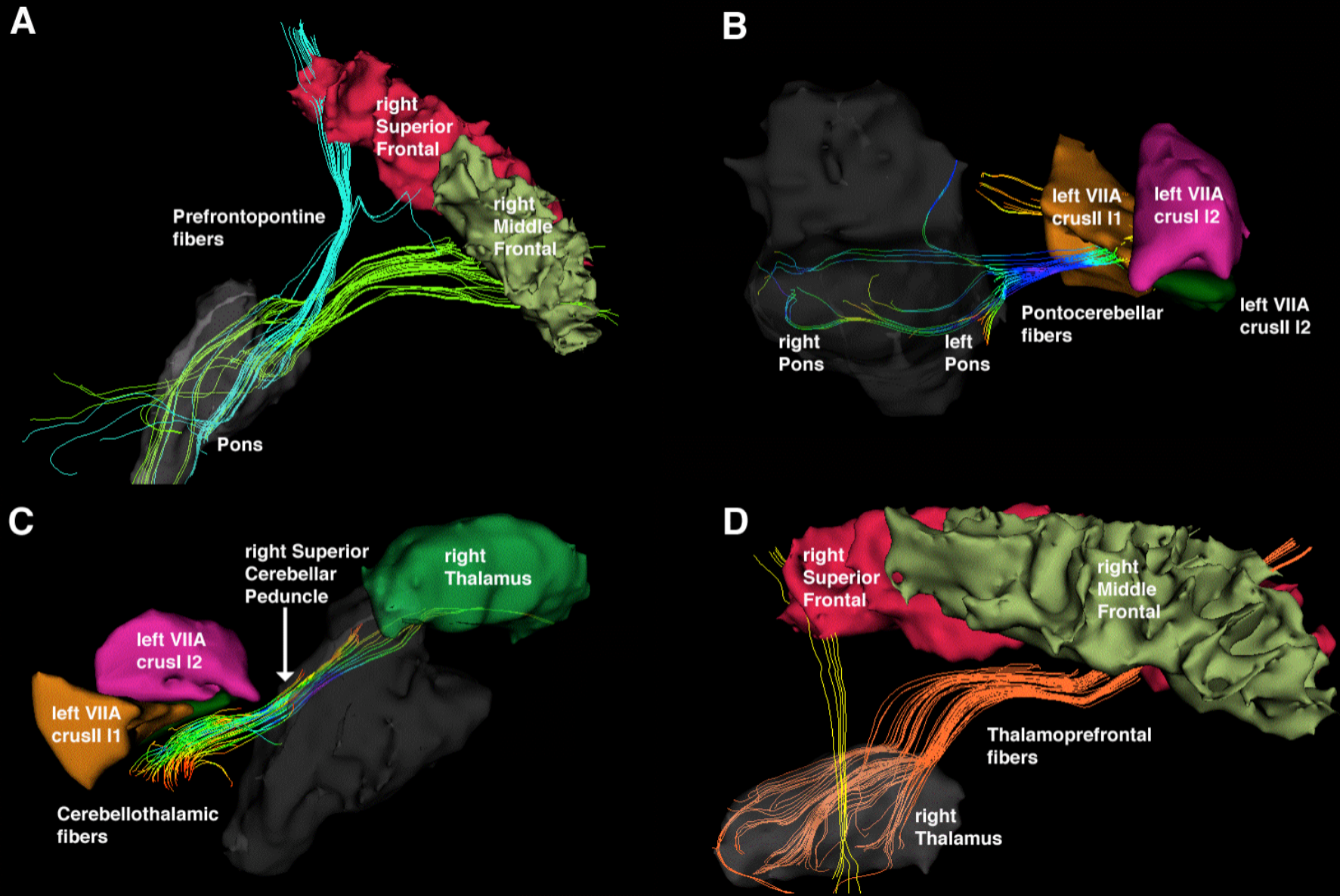
# Dorsal Streams





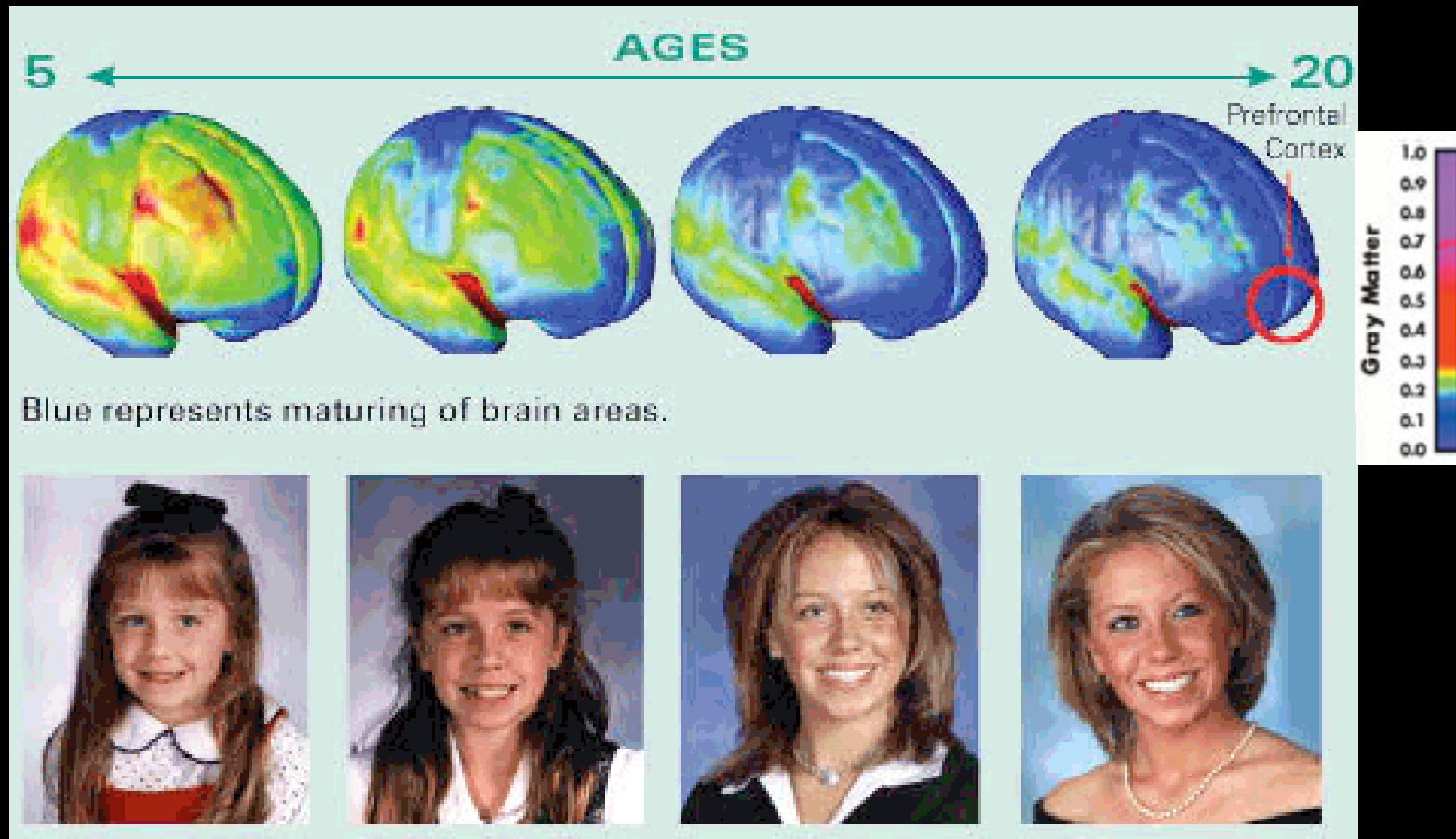


Diagrammatic representation of the cerebrocerebellar circuitry, including corticopontine connections which carry higher-order (Cognitive) information as well as sensorimotor inputs to the cerebellar cortex.



Prefrontocerebellar circuitry: A) Prefrontopontine ipsilateral projection, B) crossing pontocerebellar projection, C) crossing cerebellothalamic projection, and D) thalamoprefrontal ipsilateral projection

# Imaging Circuitries in the Developing Brain



The above composite MRI brain images show top views of the sequence of gray matter maturation over the surface of the brain.

# The Developing Brain

---

## Prefrontal Cortex

- Planning behavior
  - Use of strategies
- Cognitive flexibility (can you change your mind)
  - Fluid methods of solving problems

--The *Executive Office* of the brain is still being built during the teenage years--



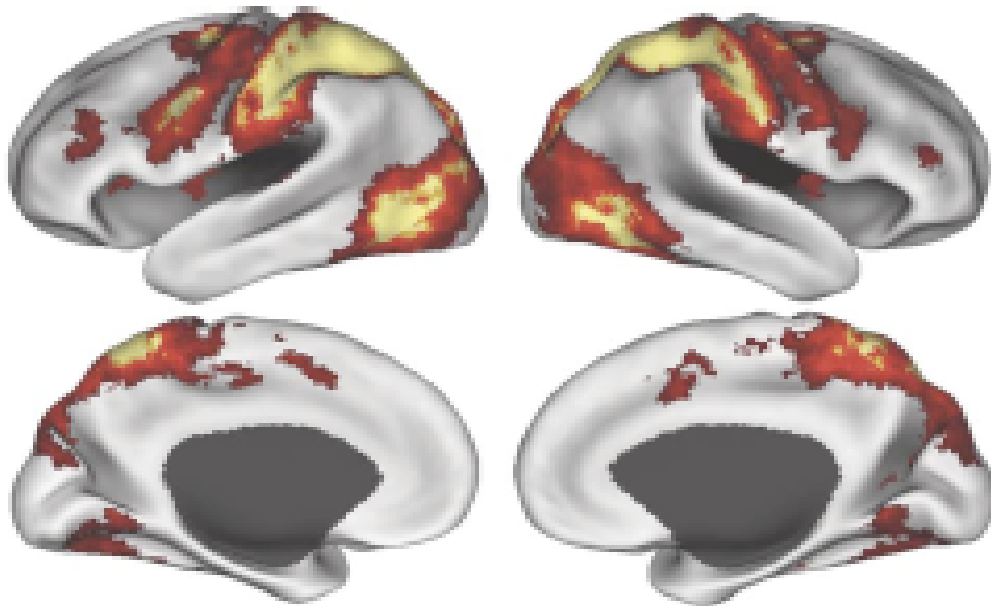
# The Developing Brain

---

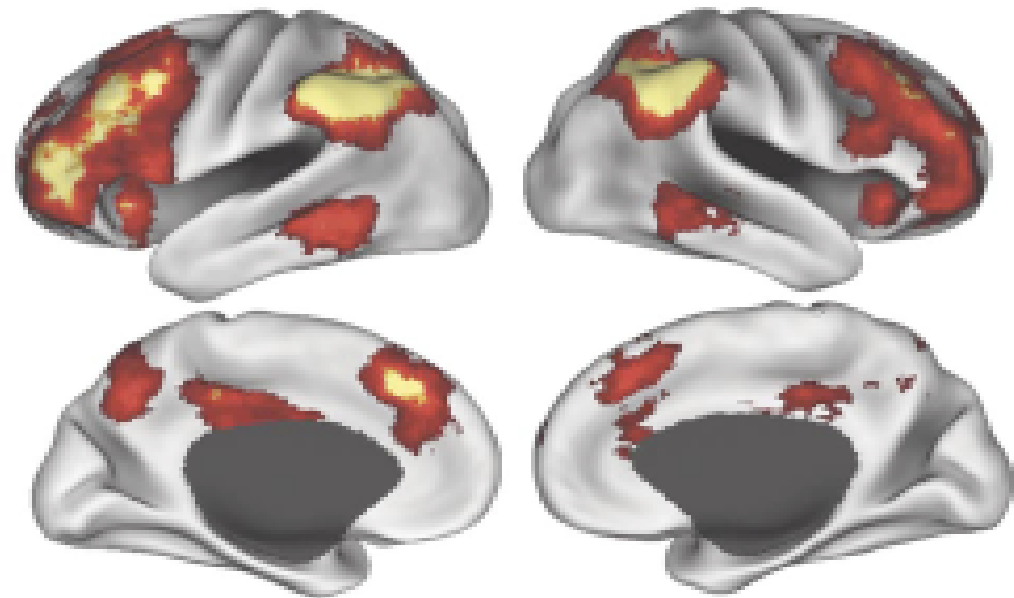
- The brain matures from the back to the front, so the frontal cortex is the last area to be completed.
- Insight, judgment, decision-making, risk taking, impulse control, are all impaired in adolescents.
- During this most vulnerable period is when teens are more likely to experiment with drugs and other damaging activities.

# Executive and Attention cognitive systems are critical during development

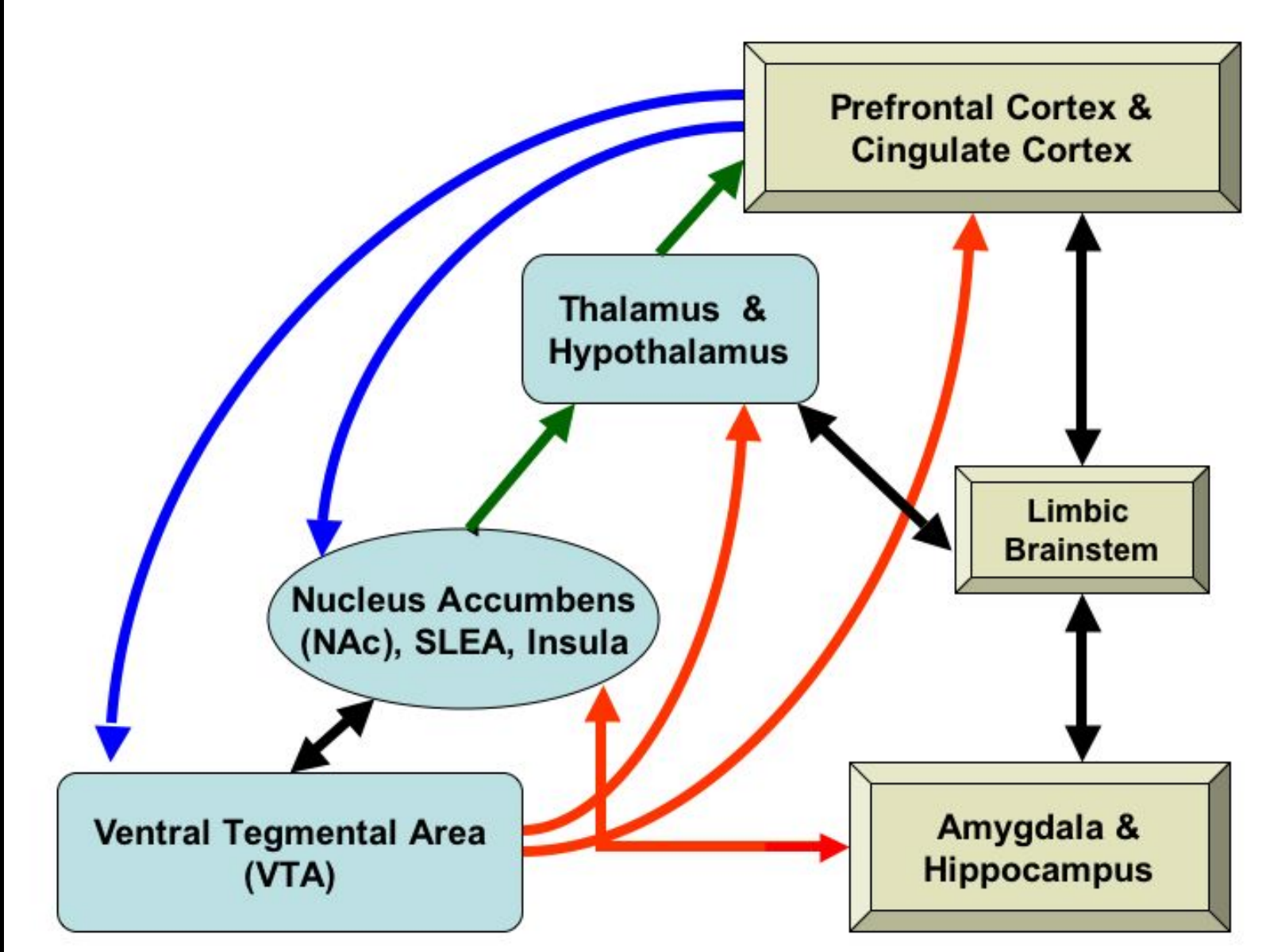
Dorsal visuospatial attention system



Frontoparietal executive control system

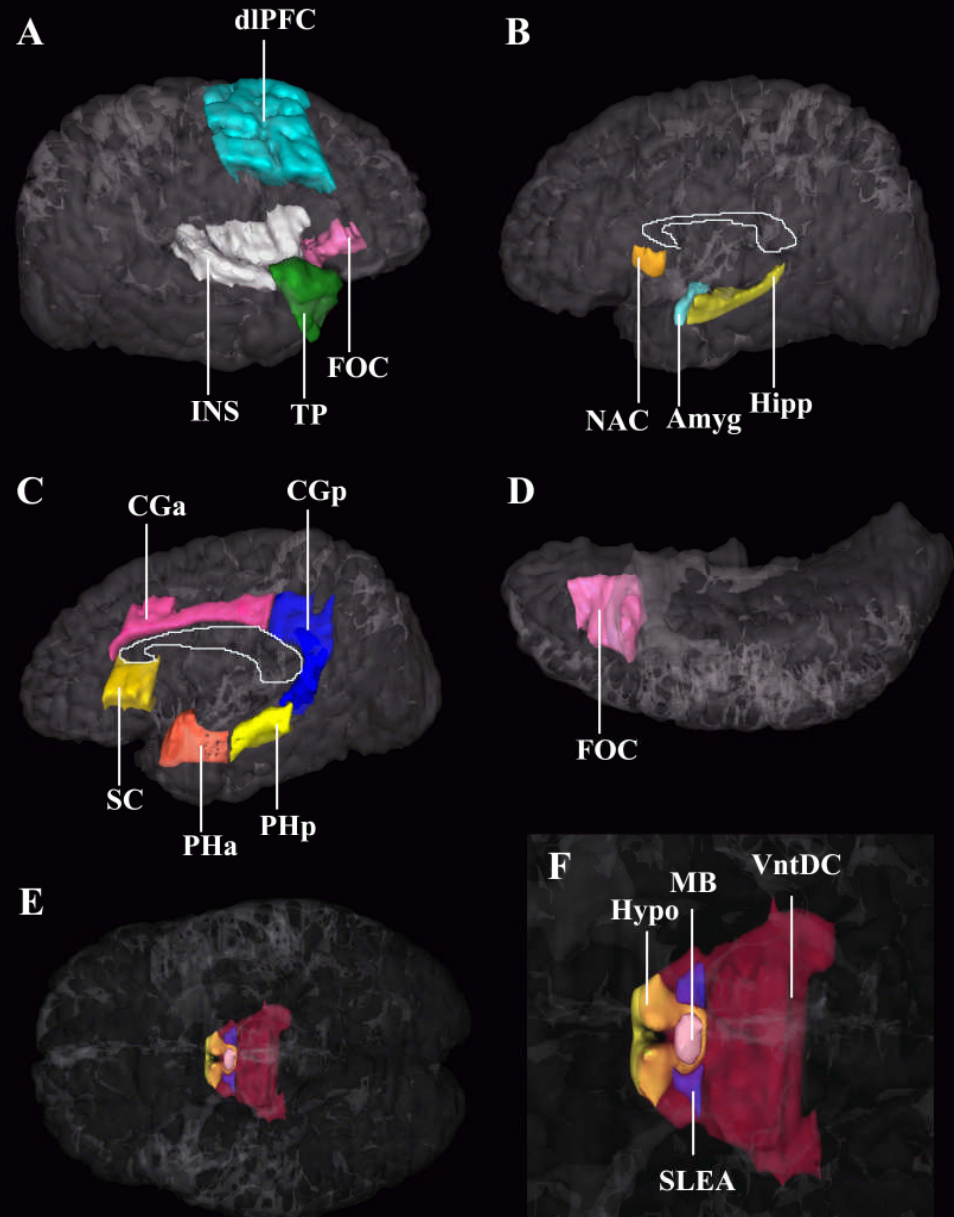
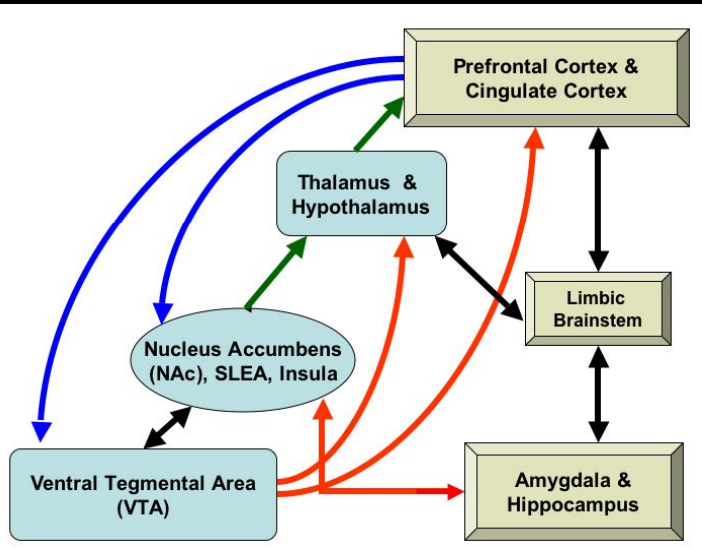


# Brain Reward Circuitry (RWC)



# Brain Reward Circuitry:

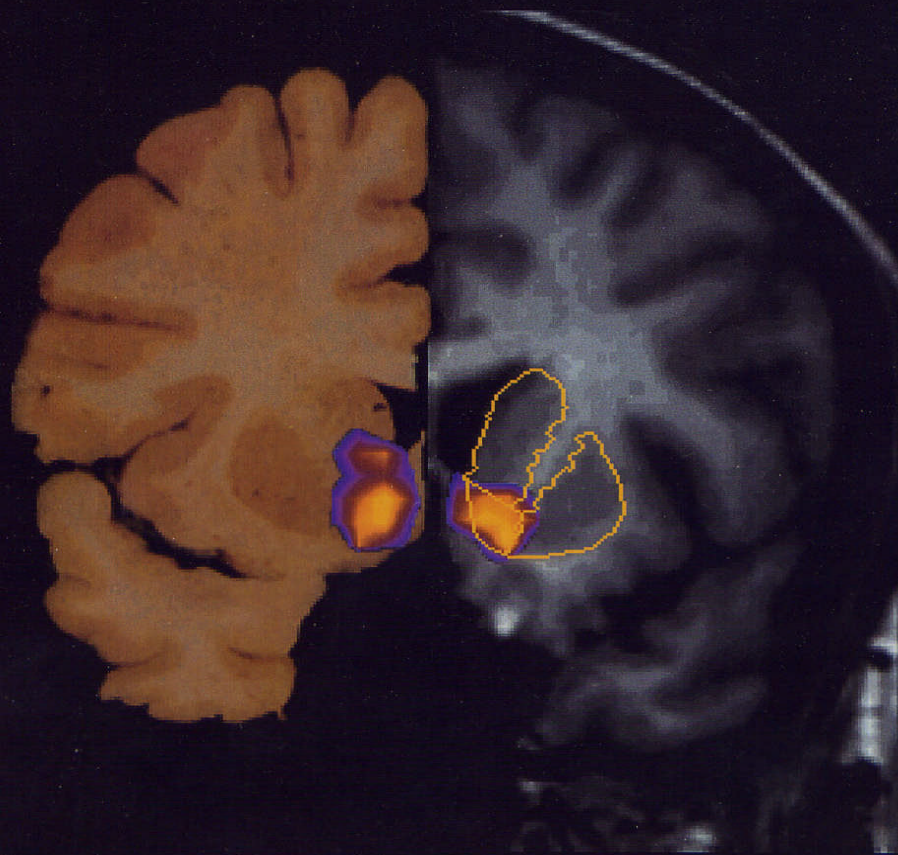
The Extended Reward and Oversight System consists of cortical and subcortical structures involved in controlling emotion and regulating sensitivity to reinforcements.



# Neuron

Volume 19 Number 3

September 1997

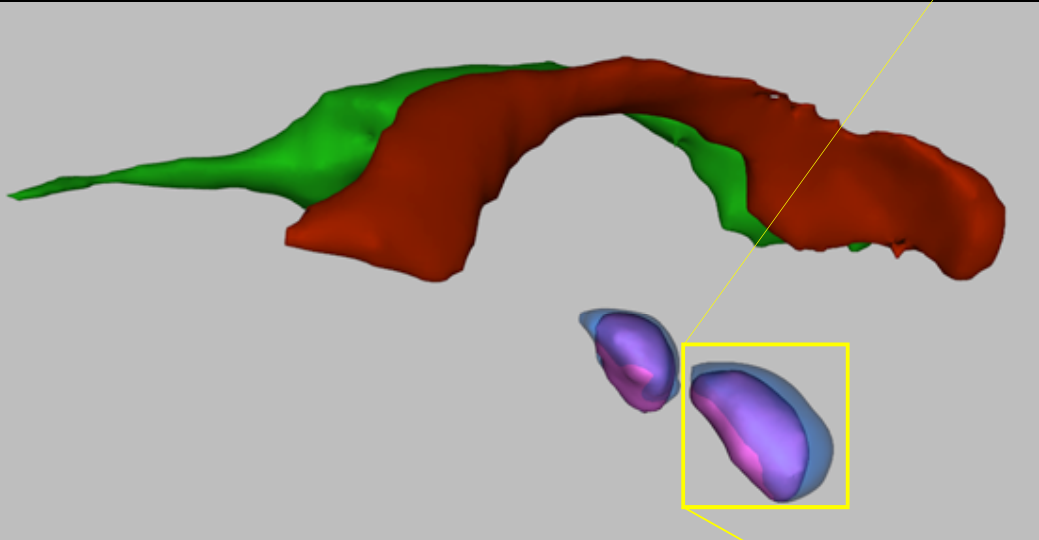


**Dynamic Mapping of Circuits Activated by Cocaine  
in the Human Brain**

*Breiter, Hyman, et al., Neuron, 1997*

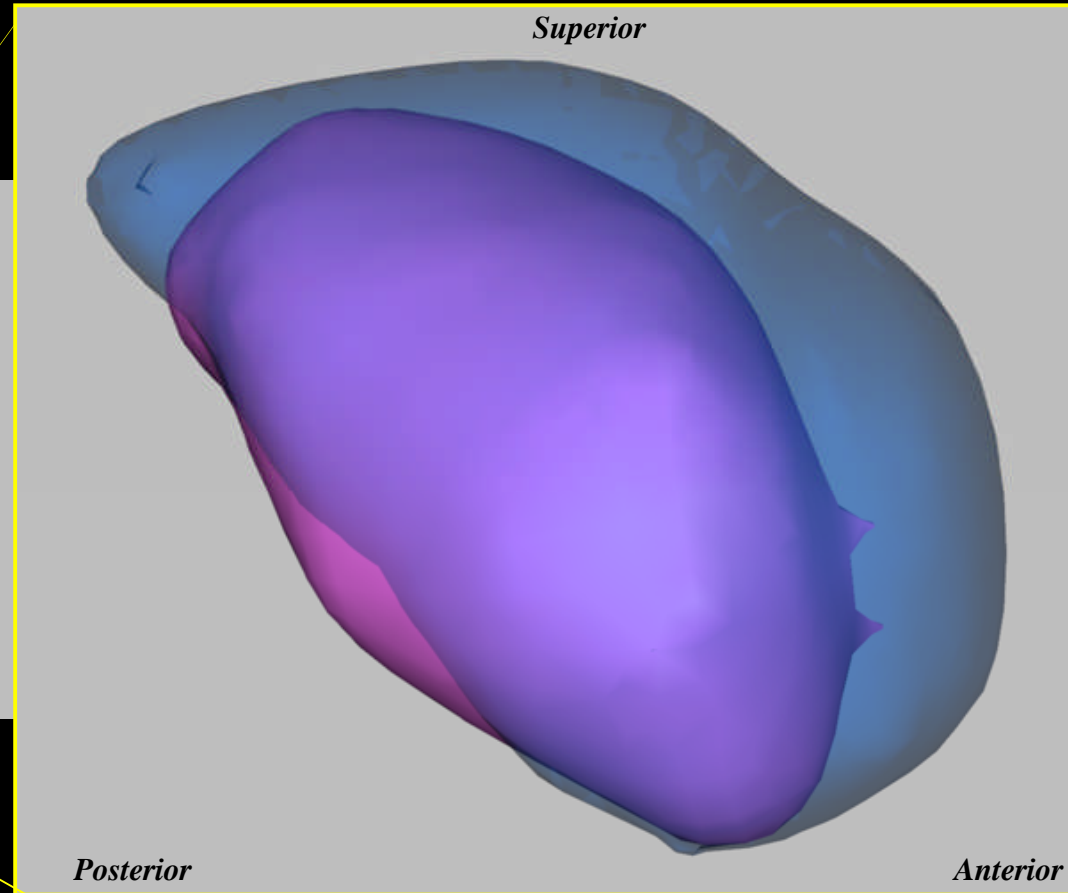
In cocaine abuse  
there are also  
observed alterations  
in the brain network  
for reward

# Amygdala in Cocaine Addiction



**Right Amygdala**

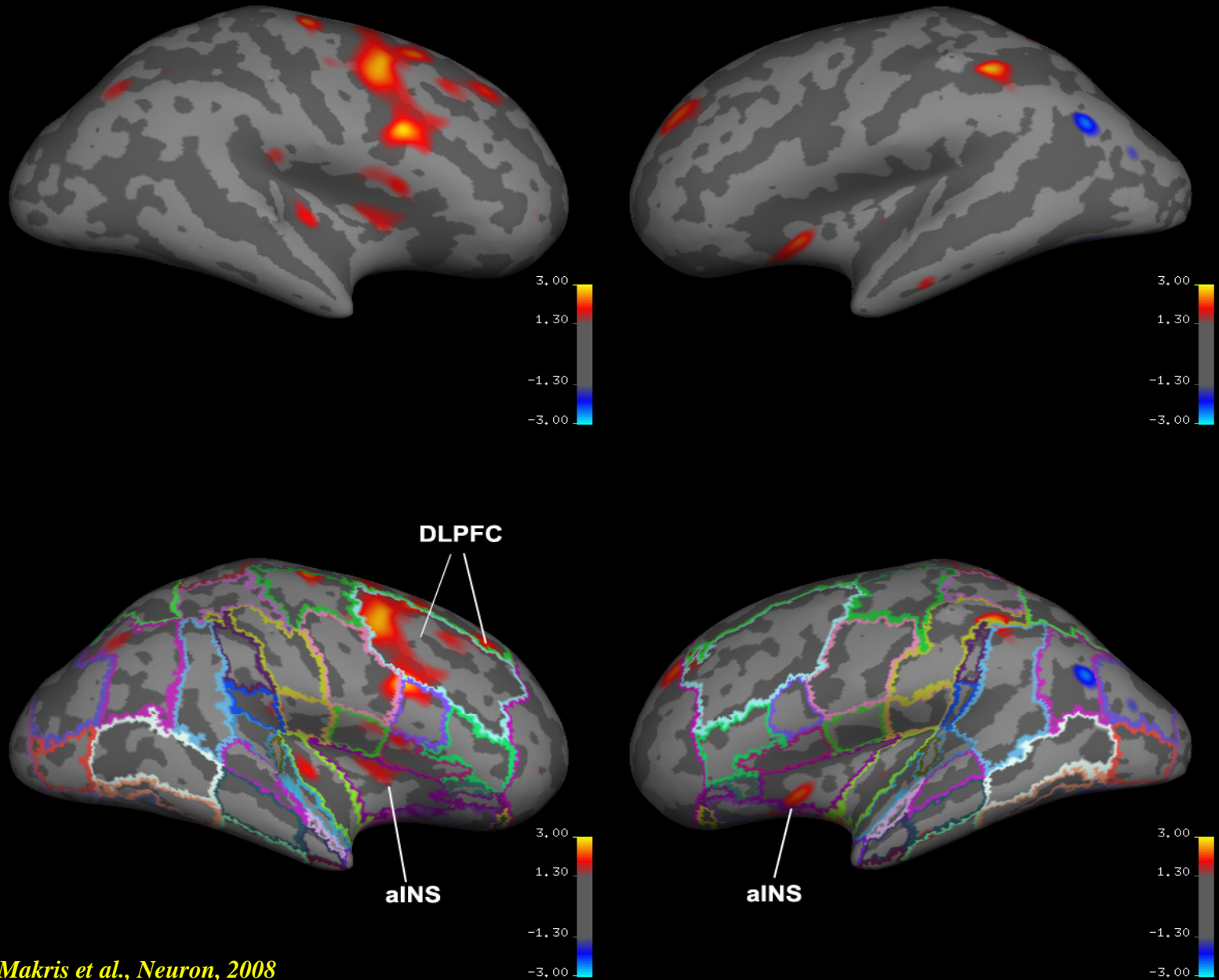
**Right Lateral Ventricle = red**  
**Left Lateral Ventricle = green**



**Patients**  
**Normal Controls**  
**Common**

**23% Volume Reduction**

# Cortical Thinning in Reward System in Cocaine Addiction

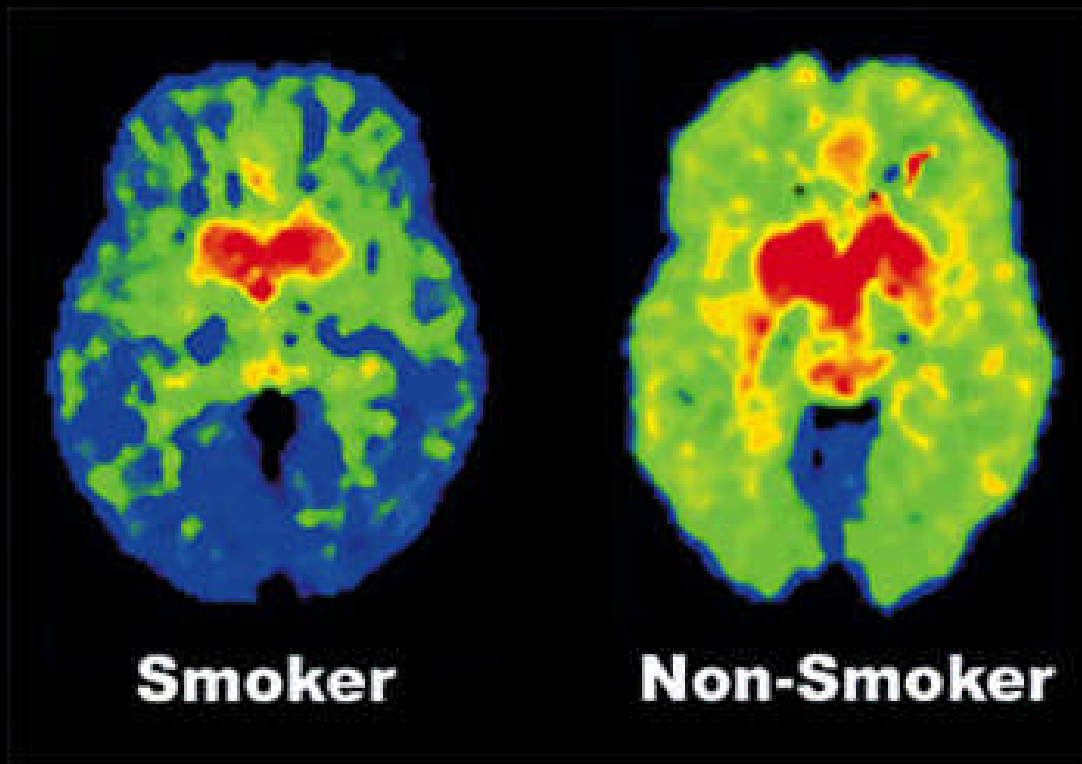

*Makris et al., Neuron, 2008*

# Tobacco: Role in Drug of Abuse

---

## Reduced brain metabolism in smokers

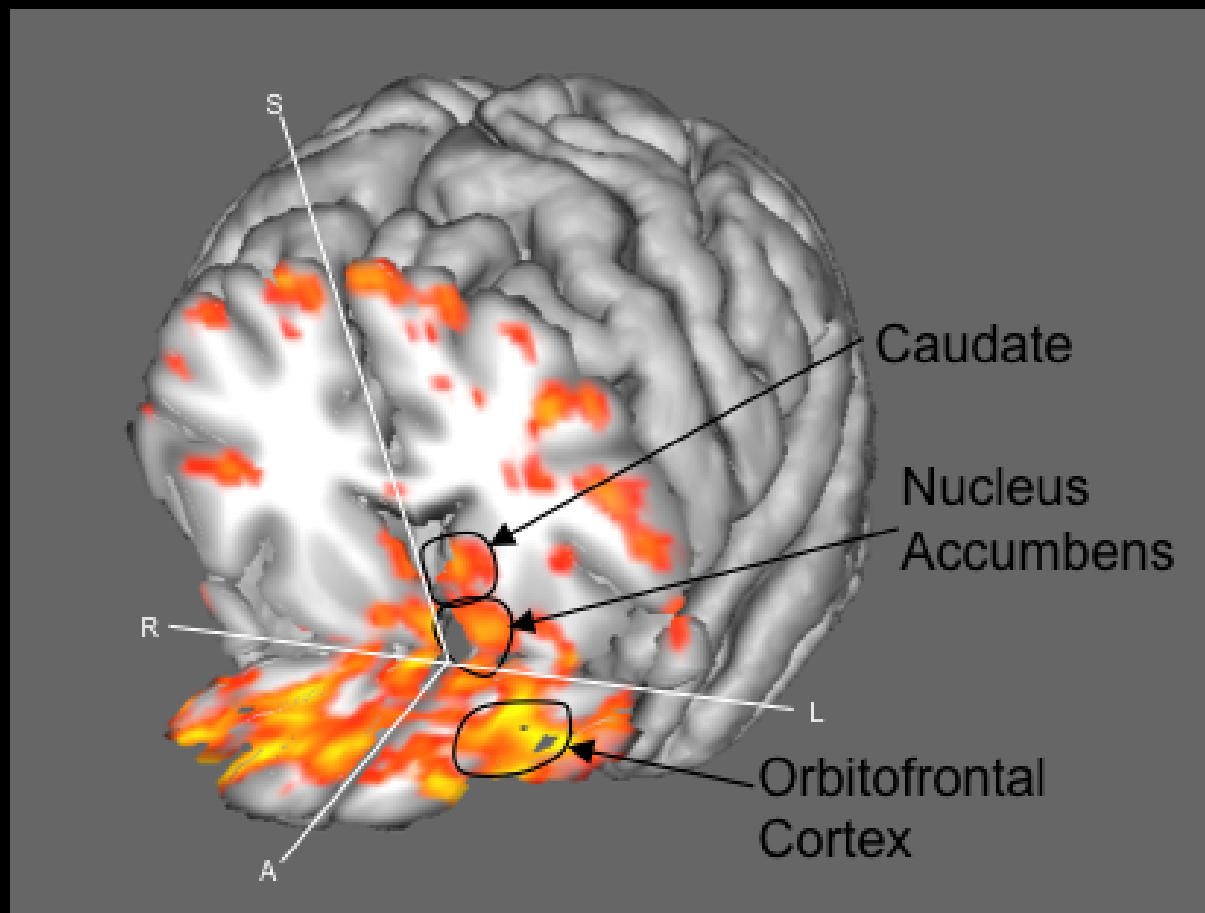


- Lower test scores
- Poor athletic ability
- Lower cognitive function
- Poor decision making



# Smoked Marijuana and fMRI

GLM analyses reveals extensive orbitofrontal and ventromedial prefrontal cortical regions with significant group differences (marihuana > placebo smoking ( $p < 0.05$  corrected, shown in red-yellow). The single-group analysis shows that marihuana activated these regions and bilateral caudate and nucleus accumbens, while placebo smoking did not.



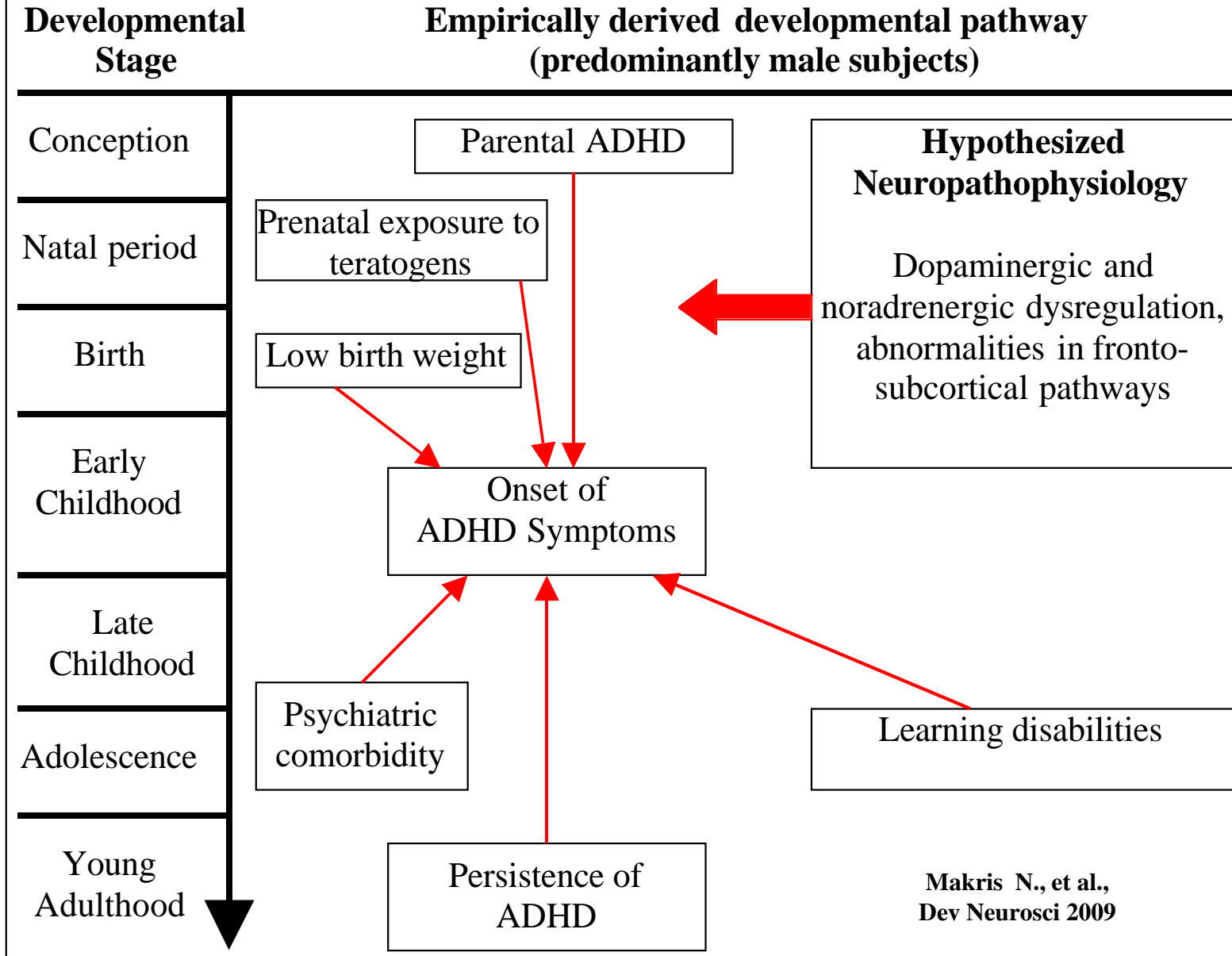
Imaging Neural Systems in Attention  
Deficit-Hyperactivity Disorder  
(ADHD)

# **Neural Systems approach addresses at least three questions**

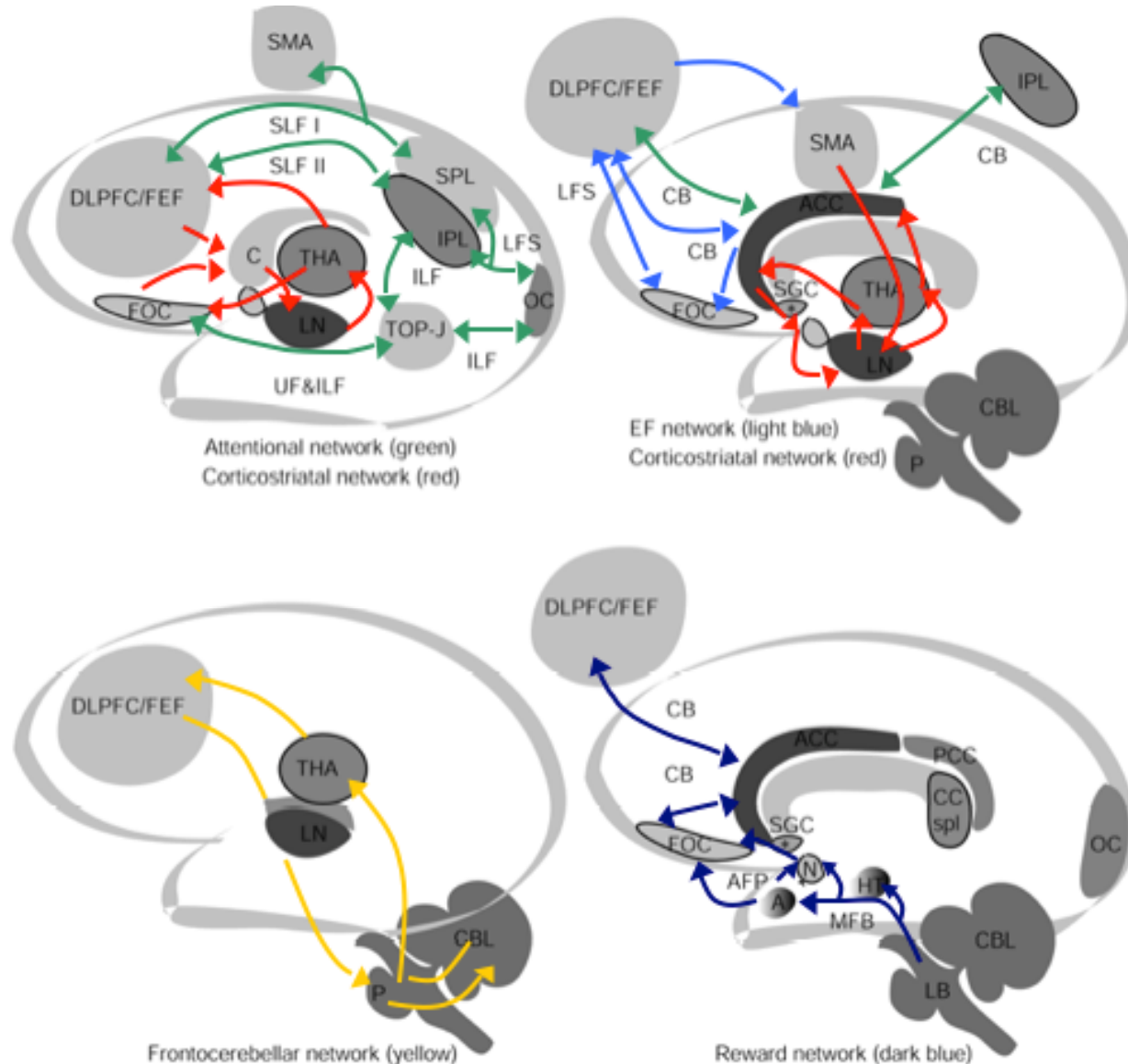
---

- 1) Are the structures shown to be altered in ADHD indeed component parts of well-understood neural systems?**
- 2) Do these structural neural systems correlate with specific behaviors?**
- 3) Are these neural systems associated with specific genotypes?**

**Figure 1: Conceptual model of the pathophysiology and etiology of ADHD**



## Functional neuroanatomy of neural systems involved in psychiatric disorders



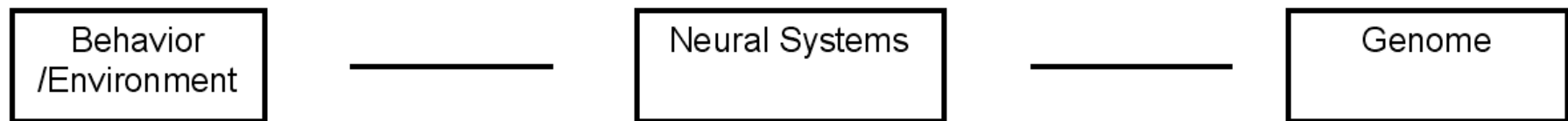
A=amygdala; ACC=anterior cingulate cortex; AFP=amygdalofugal pathway; C=caudate nucleus; CB=cingulum bundle; CBL=cerebellum; CCspl=splenium of corpus callosum (incl. isthmus); DLPFC=dorsolateral prefrontal cortex; FEF=frontal eye field; FOC=fronto-orbital cortex; HT=hypothalamus; ILF=inferior longitudinal fascicle; IPL= inferior parietal lobule; LB=limbic brainstem; LFS=local fiber system; LN=lenticular nucleus; MFB=medial forebrain bundle; N=nucleus accumbens; OC=occipital cortex; P=pons; PCC=posterior cingulate cortex; SGC=subgenual cingulate cortex; SLF=superior longitudinal fascicle; SMA=supplementary motor area; SPL=superior parietal lobule; THA=thalamus; TOP-J=temporo-occipito-parietal junction; UF=uncinate fascicle

## A major goal of MRI brain research is the study of endophenotypes

---

Once we quantify **imaging-based markers (or endo-phenotypes)**, for example, size of brain structures (such as cingulate cortex or prefrontal cortex) or **neural systems** (such as the reward, the attention or executive function systems), we may be able to **diagnose** psychiatric illnesses, **assess** treatment and **identify genes** that will lead to **new medications**.

**Figure 4: Neural systems biology acts as an interface between behavior and the genome**

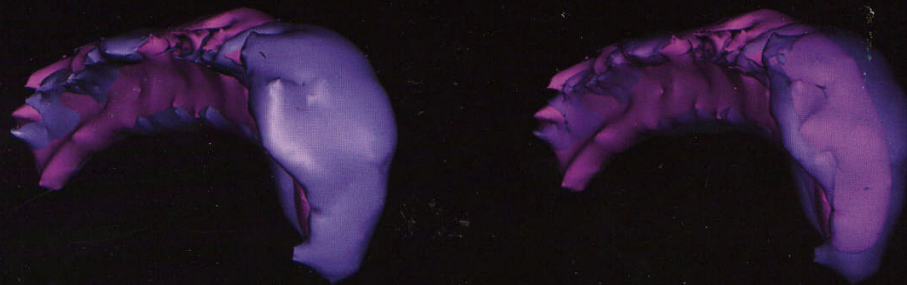

*Systems biology acts as an interface between the **behavior**/environment and **genome**/epigenome.*

# Biological Psychiatry

Volume 60, Number 10

November 15, 2006



ISSN 0006-3223

[www.sobp.org/journal](http://www.sobp.org/journal)

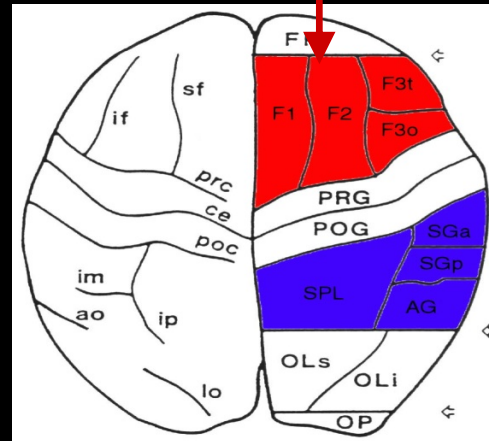
Official Journal of the Society of Biological Psychiatry

# ADHD: Neurobiological Basis – Neural Systems

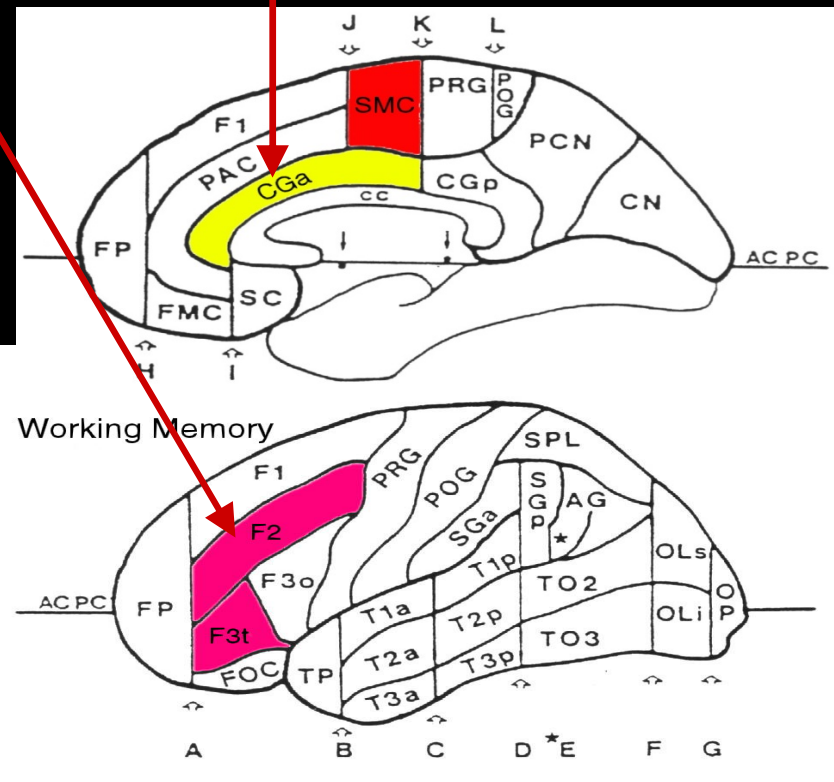
## Attention Networks

ORIENTING (SELECTIVE ATTENTION)

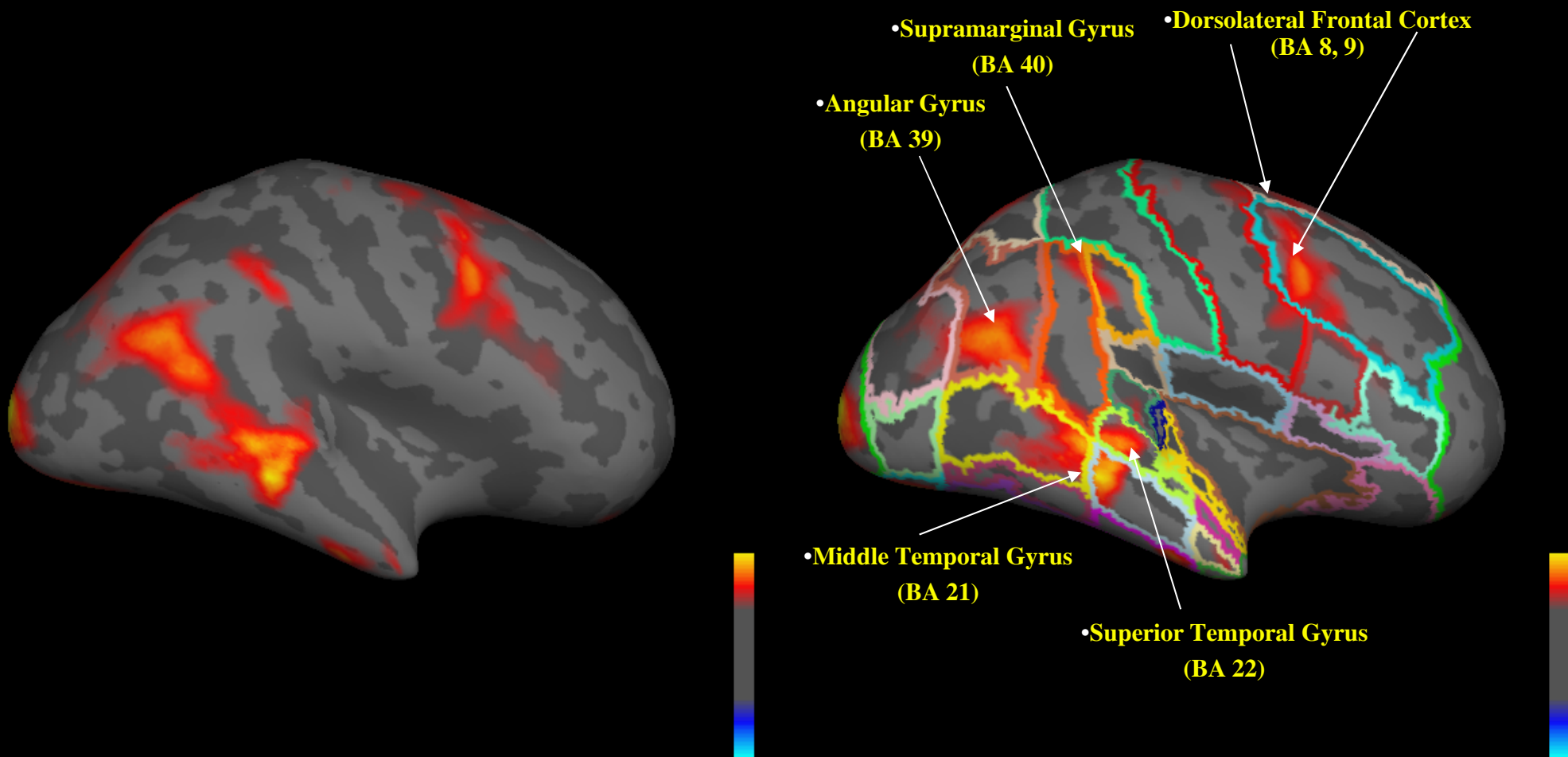
ALERTING

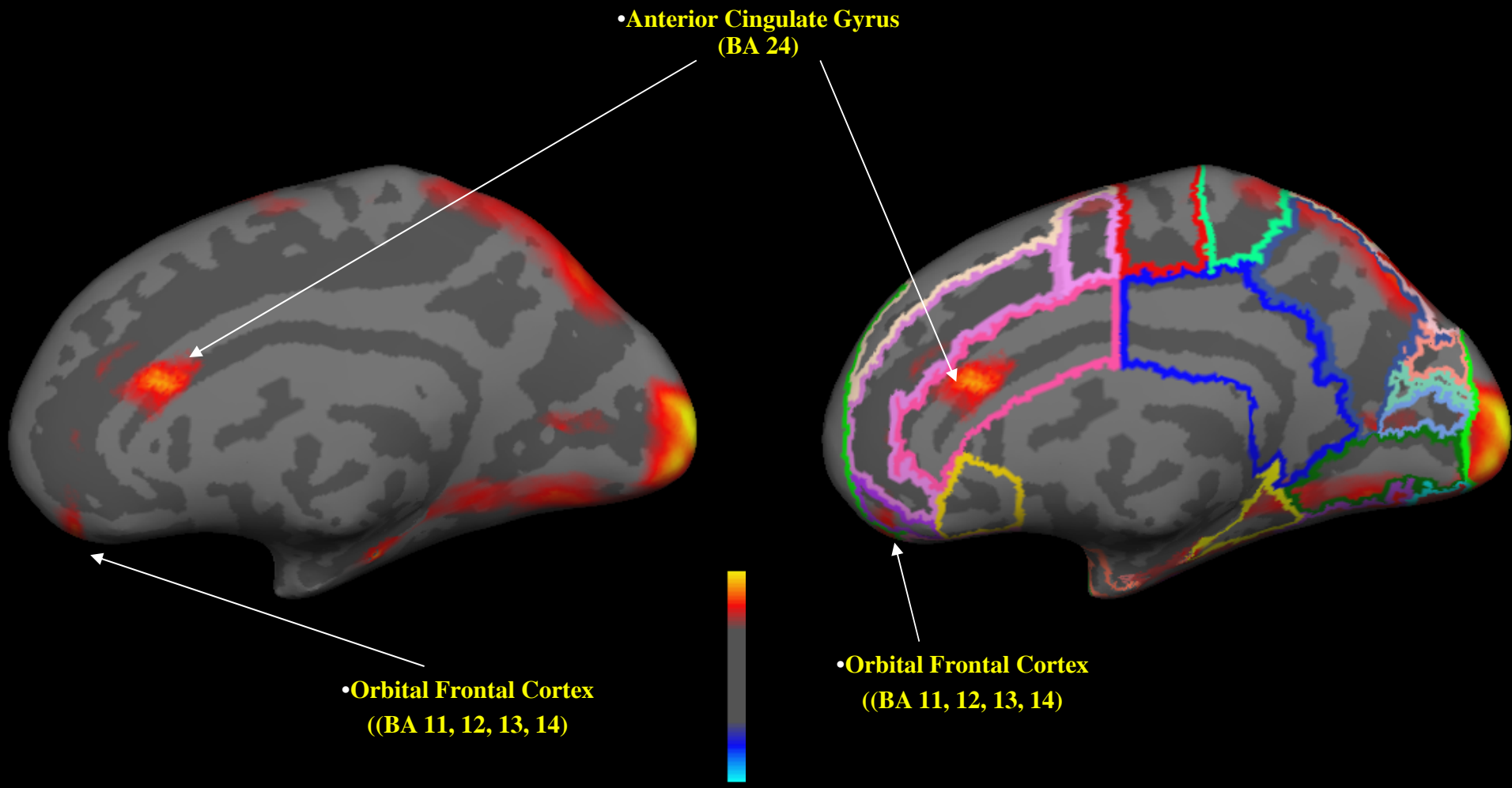


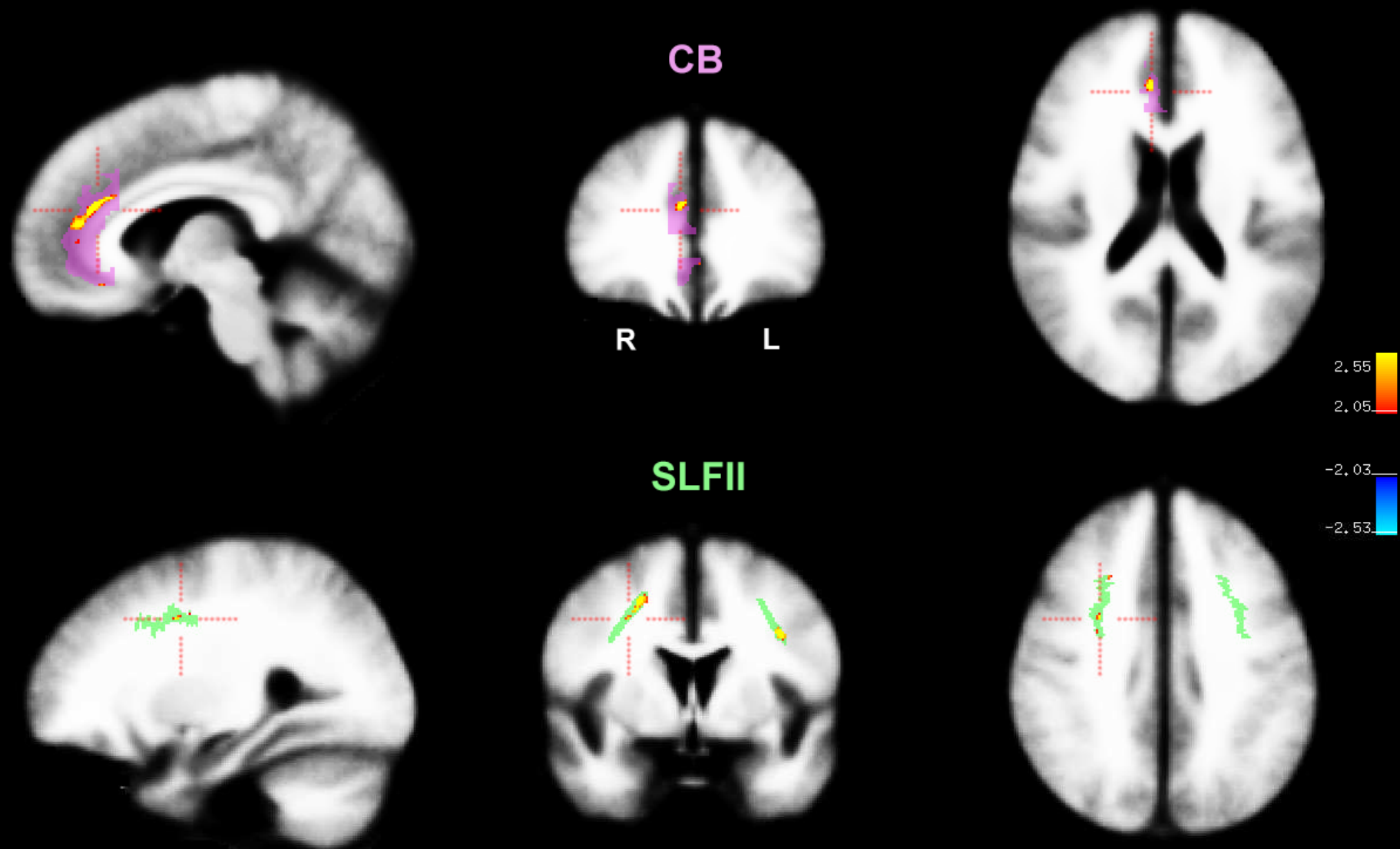
EXECUTIVE CONTROL











Fractional anisotropy decrease in ROIs for the cingulum bundle and the superior longitudinal fascicle II (SLF II) in adults with ADHD

Makris, Seidman et al., *Cerebral Cortex*, 2008

# Some challenges in psychiatric imaging

Diagnosis at a brain circuitry level

Clear localization of abnormalities

Instantaneous results with treatment

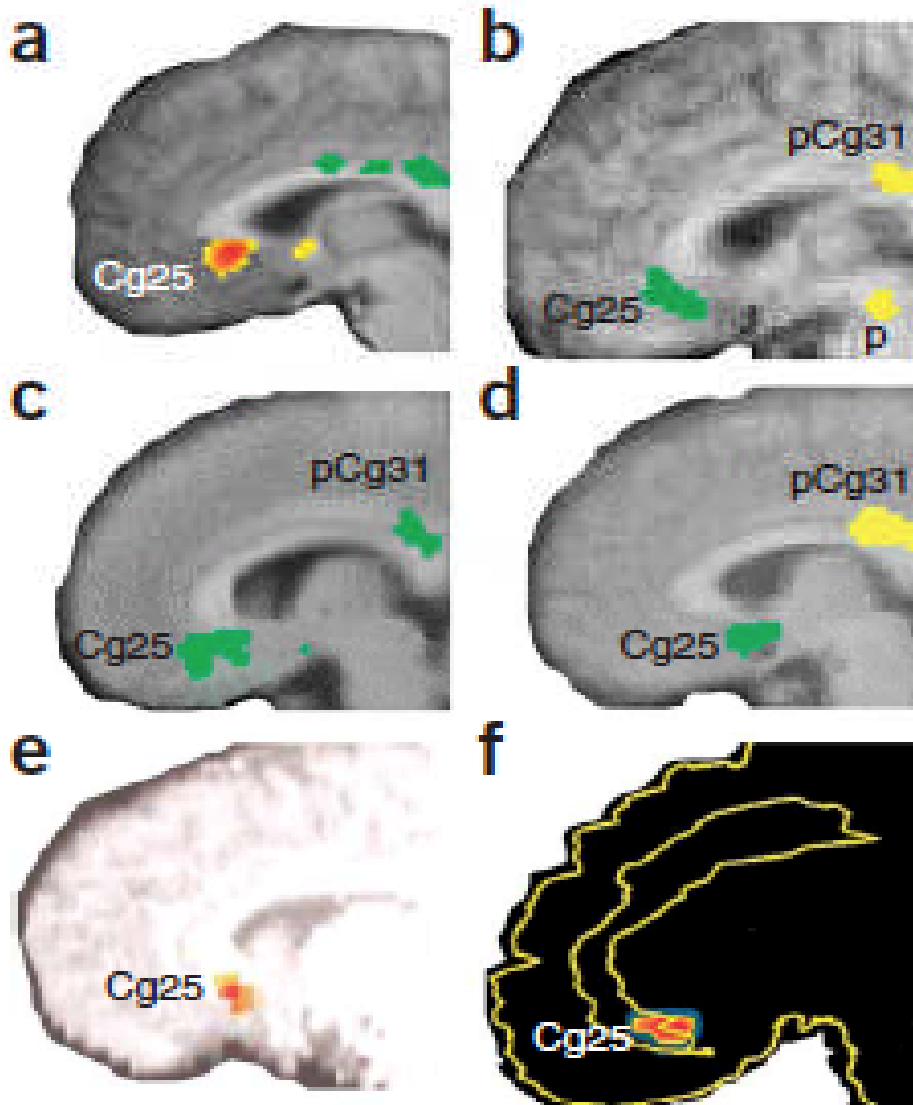
Use of advanced mathematical  
modeling

## Subgenual Cingulate Cortex (BA 25)

Increased activity with sadness and depression (a, b) (using PET)

Decreased activity with chronic fluoxetine treatment for depression (c) or natural placebo recovery (d)

Decreased activity in responders vs non-responders to CBT and citalopram for social phobia (e, f)



**Figure 1** Subgenual cingulate cortex activation across studies. (a) Transient sadness in healthy volunteers increases activity (red) in Cg25 (arrow) measured with positron emission tomography (PET) (from ref. 12. Reprinted with permission from the *American Journal of Psychiatry*, copyright 1999, American Psychiatric Association.). (b) Decreased Cg25 activity (green) with chronic fluoxetine treatment for depression. (c) Cg25 decrease (green) in recovery with chronic fluoxetine from Parkinson's disease-related depression. (d) Natural recovery with decreased Cg25 activity (green) in patients treated with placebo. Panels b–d reprinted from ref. 11 by permission of Oxford University Press. (e) Predictors of response in subjects responding to CBT for depression included low pretreatment Cg25 activity (red) (from ref. 15. Reprinted with permission from the *American Journal of Psychiatry*, copyright 1999, American Psychiatric Association.). (f) Subgenual cortical decreased activity (red) was common in responders compared with nonresponders for those responding both to citalopram and to CBT for social phobia (from ref. 16. Reprinted from *Archives of General Psychiatry*, copyright 2002, American Medical Association. All rights reserved.).

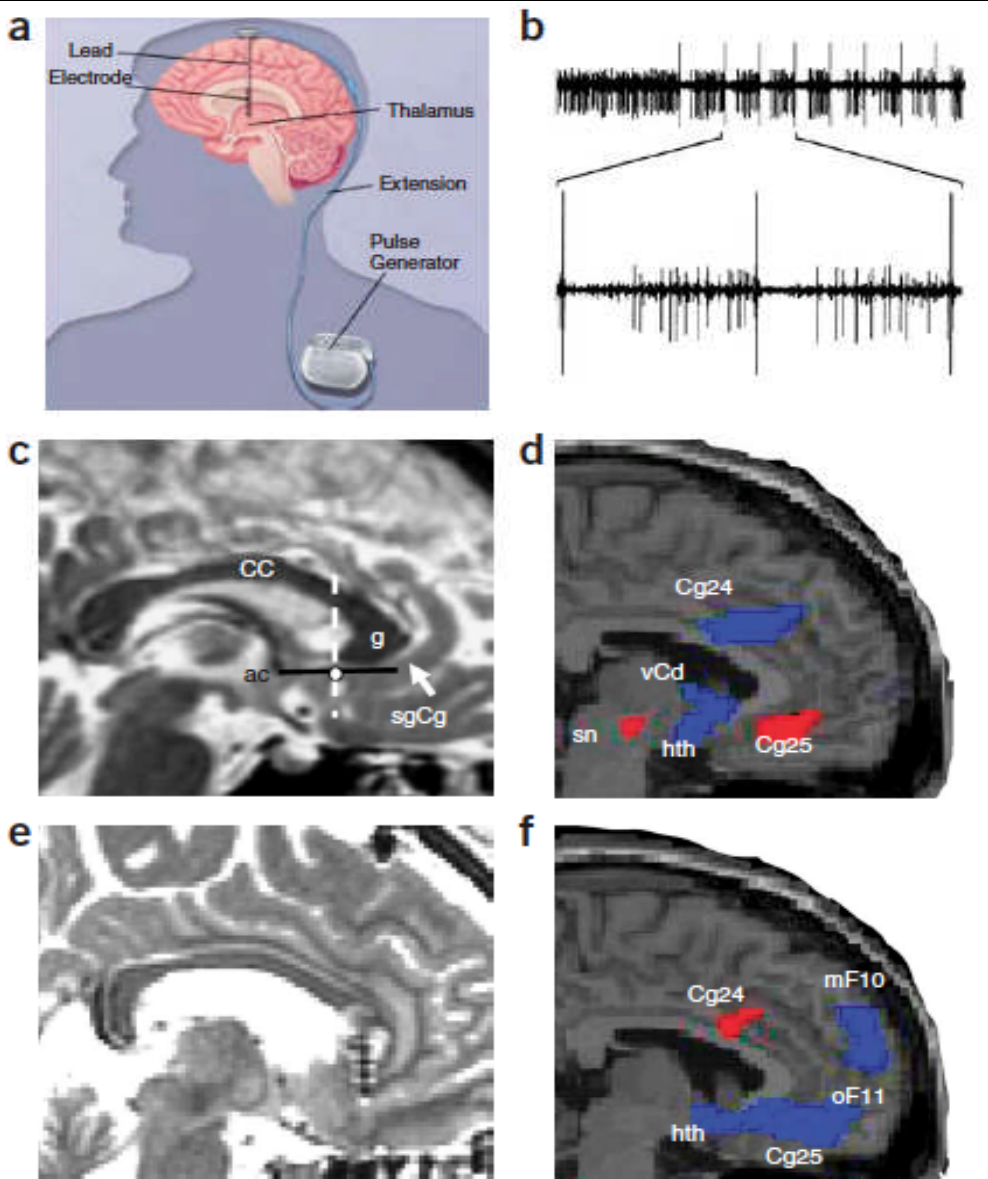
## Deep Brain Stimulation (DBS)

**One possible mechanism: DBS-induced inhibition [e.g., DBS in PD at GPi: discharges from high-frequency discharge neurons showing inhibitory periods after each stimulus pulse (a, b)]**

**DBS at Cg25 for depression (c-f)**

**Preoperative (d)**

**At 3 months in treatment responders (f)**



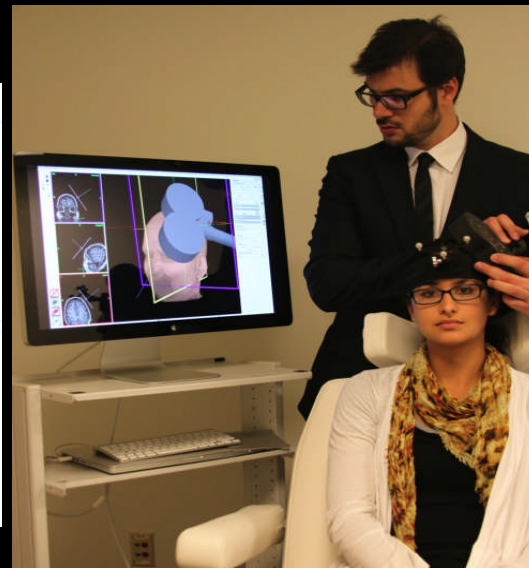
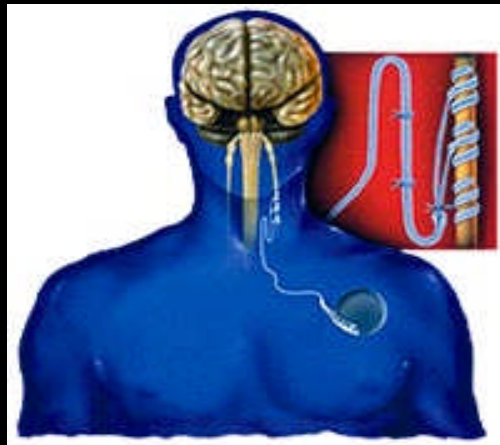
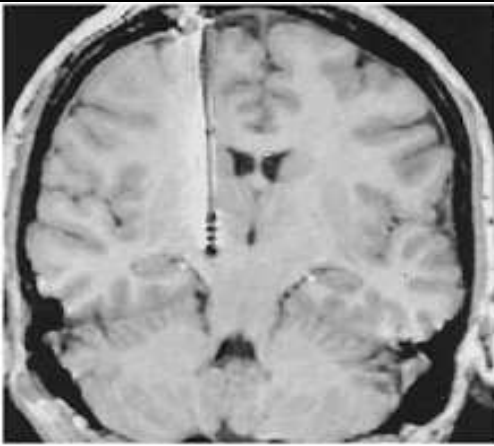
**Figure 4** Deep brain stimulation. (a) Schematic of DBS used for Parkinson's patients (modified from WebMD, [http://www.medicinenet.com/deep\\_brain\\_stimulation/article.htm](http://www.medicinenet.com/deep_brain_stimulation/article.htm)). (b) One possible mechanism of action of DBS-induced inhibition: recordings from a globus pallidus internus (GPi) high-frequency-discharge neuron showing inhibitory periods after each stimulus pulse (50  $\mu$ A) (from ref. 100. Copyright 2000 by American Physiological Society. Reproduced with permission of American Physiological Society via Copyright Clearance Center.). (c) Preoperative MRI target localization for DBS for refractory depression. White dot, location of the sgCg white matter targeted for electrode placement in the DBS depression study, shown in a single subject; white arrow, sgCg gyrus; dotted line, anterior-posterior location of the electrode along the line (black) between anterior commissure and genu of the corpus callosum. (d) Baseline PET-derived blood flow: depressed patients show increased activity (red) in Cg25 compared with healthy controls. (e) Postoperative MRI in a single DBS patient showing the electrode tip in the sgCg white matter. (f) At 3 months, regions of blood flow change measured with PET in treatment responders show decreased activity (blue) compared with pretreatment. Panels c–f reprinted by permission from an article published in *Neuron*, ref. 58, copyright Elsevier 2005. CC, corpus callosum; ac, anterior commissure; g, genu of the corpus callosum; sgCg, subgenual cingulate; Cg24, cingulate area 24; sn, substantia nigra; hth, hypothalamus; mF10, medial frontal area 10; oF11, orbito-frontal area 11.

# Brain Stimulation-Neuromodulation

## Invasive

Deep Brain Stimulation (DBS)

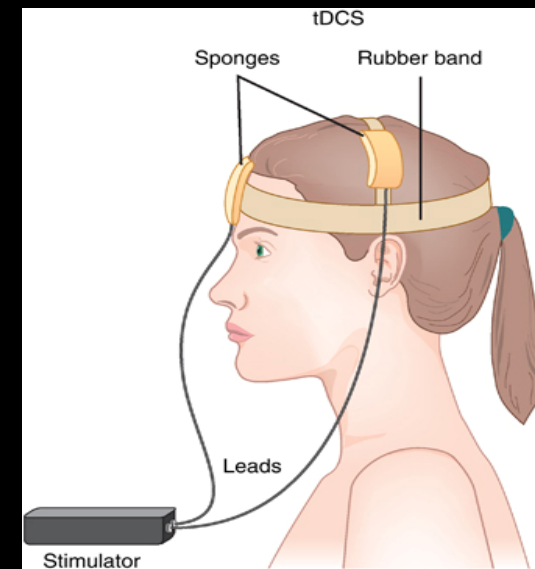
Vagal Nerve Stimulation (VNS)



## Noninvasive

Transcranial Magnetic Stimulation (TMS)

Transcranial Direct Current Stimulation (tDCS)



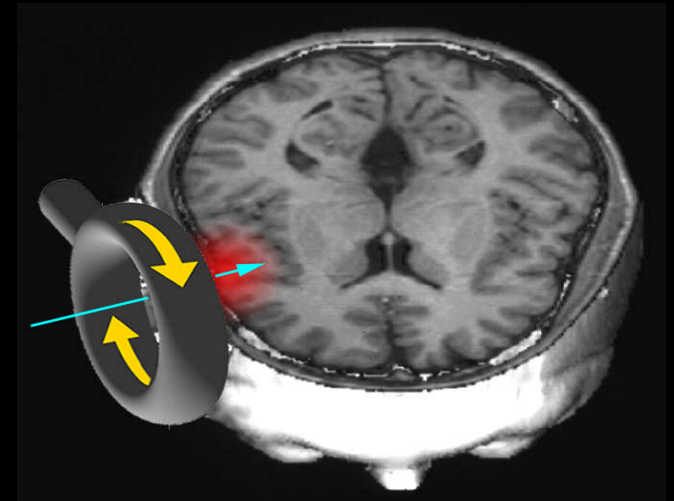
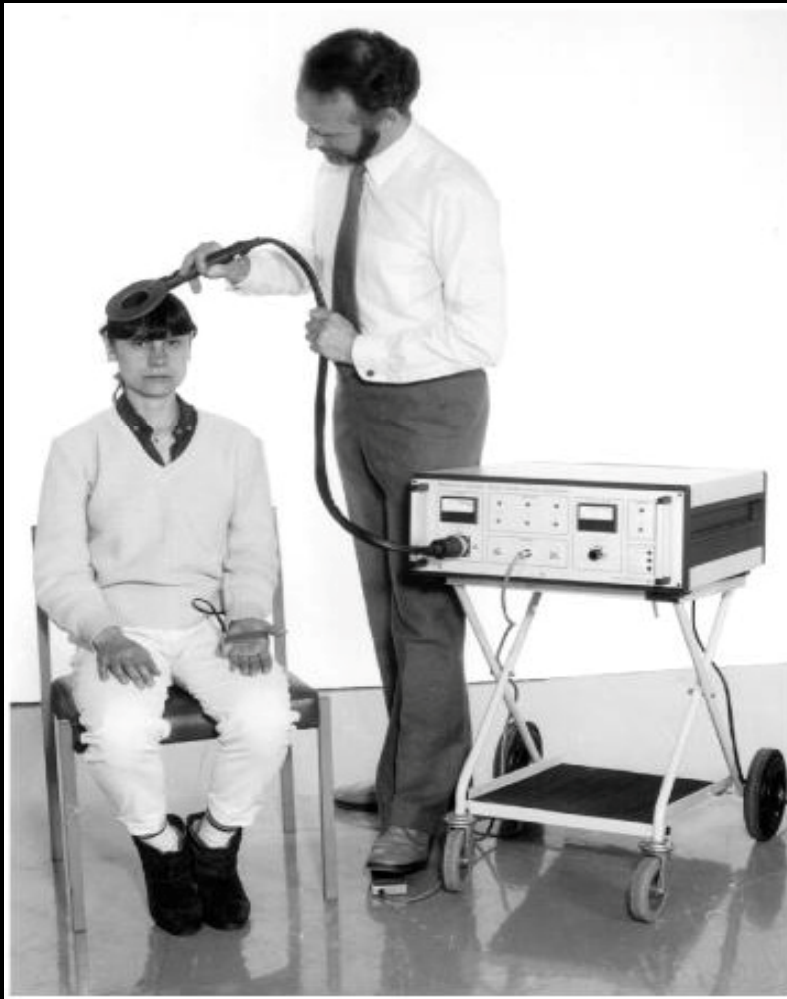# Neuromodulation

- **Neural Pacemaker:** Forces a population of neurons to fire at a specific frequency, changing excitability and functional connectivity both locally and within a given network
- Chronic vs. Discrete Stimulation
- Invasive vs Noninvasive
- All aim to induce adaptive neuroplasticity



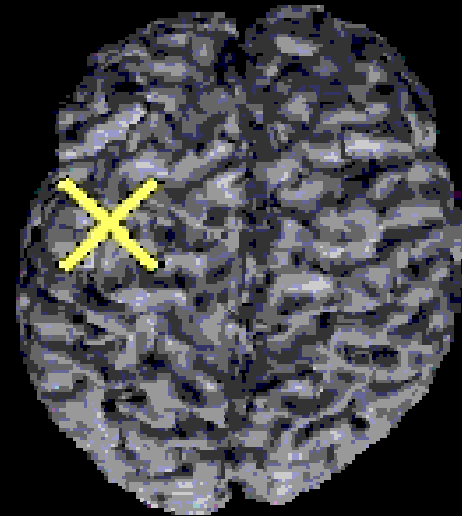
# Transcranial Magnetic Stimulation

Anthony Barker 1984

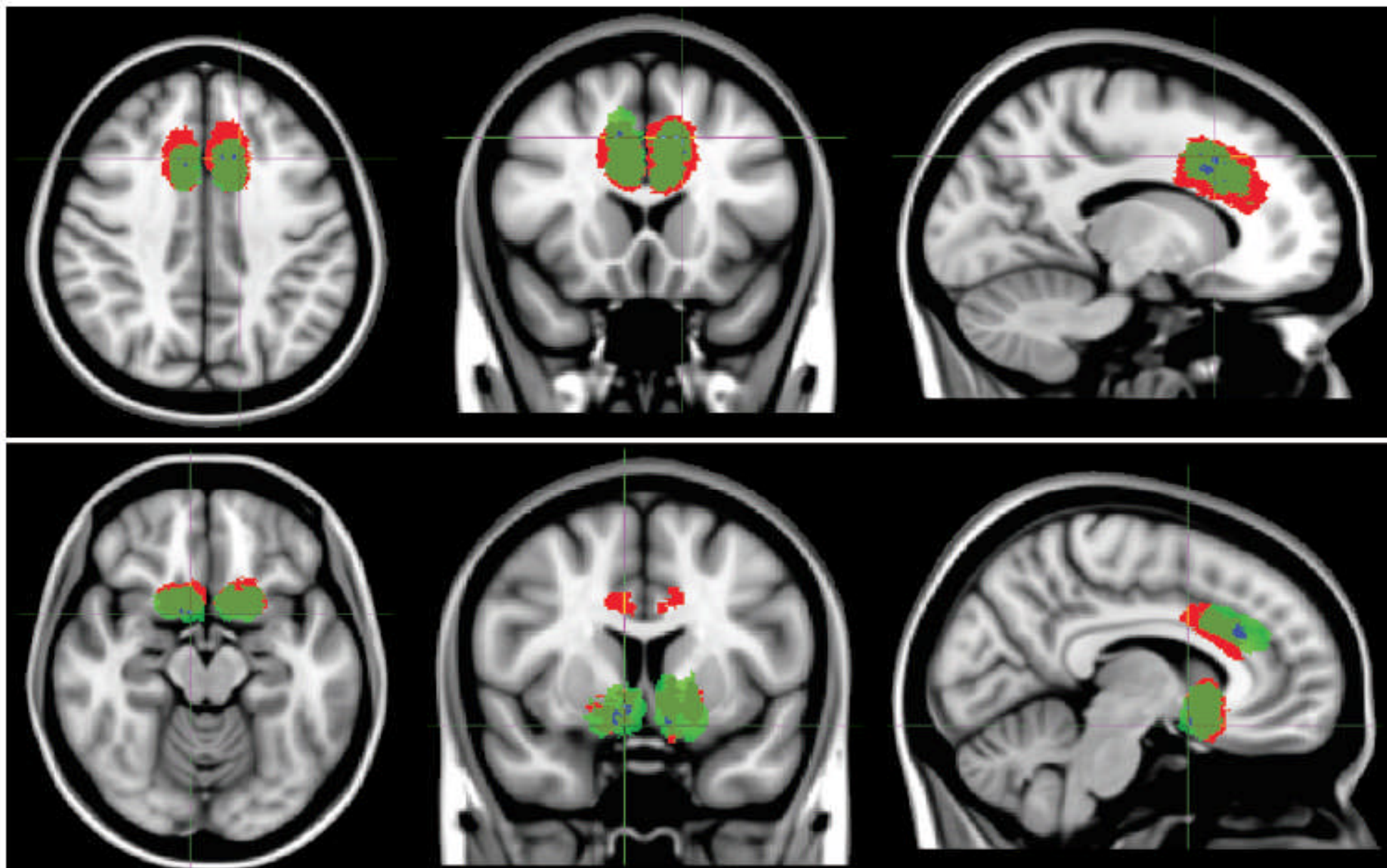


# Transcranial Magnetic Stimulation

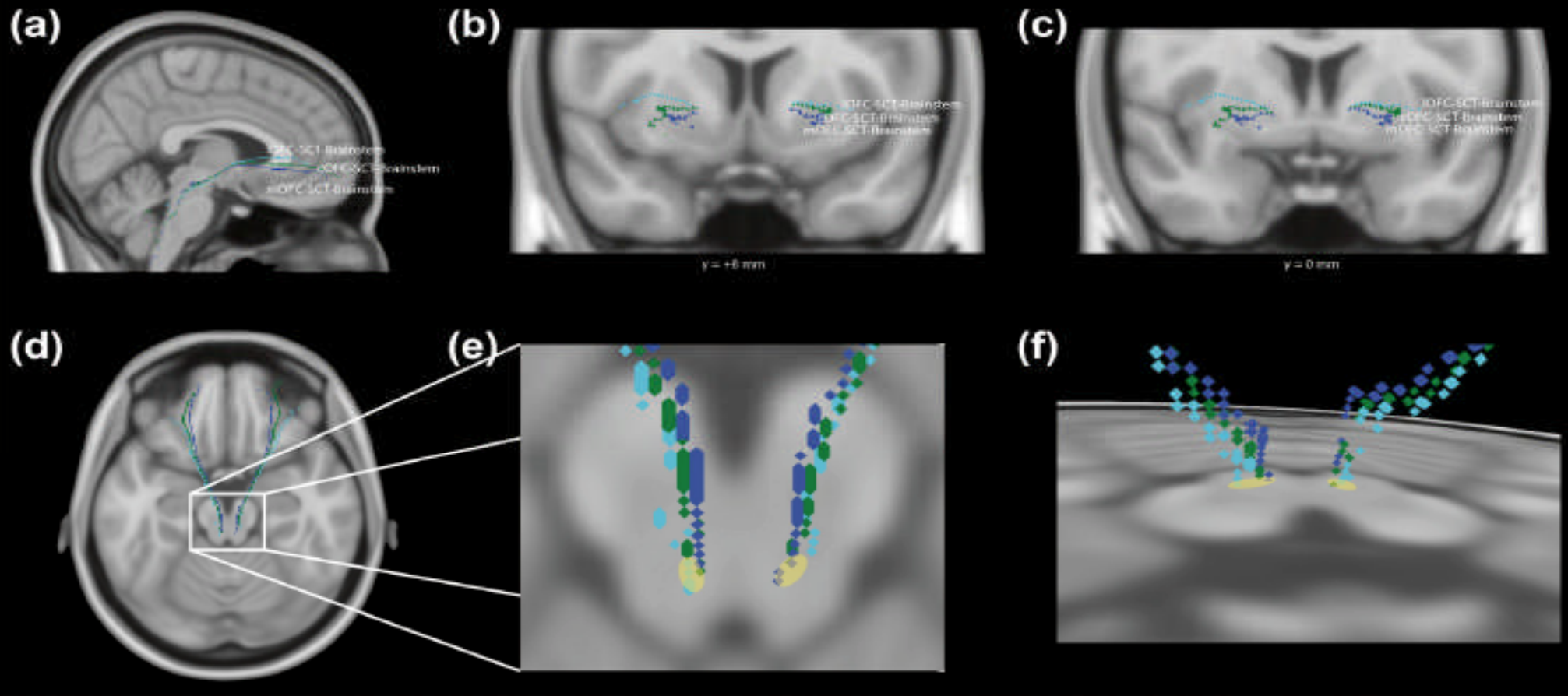
Anthony Barker 1984



# Imaging in Deep Brain Stimulation



**FIG. 8.** Voxel-based lesion-outcome mapping for anterior cingulotomy and limbic leucotomy. Voxels found to be significant by VLSM are shown in *blue* (subareas within *green* areas). Nonresponder (*red*) and responder (*green*) lesion masks were collectively summed and are projected on the T1-weighted MNI152 template. **Upper:** Anterior cingulotomy. Axial, coronal, and sagittal images (*left to right*). **Lower:** Limbic leucotomy. Axial, coronal, and sagittal images (*left to right*). *Yang et al., Journal of Neurosurgery, 2013*



**Fig. 6** 3D Projections of Talairach Coordinates for Orbitofrontal Cortex-Brainstem Tract (a) 3D sagittal, (b) coronal (level of the nucleus accumbens, Talairach y-coordinate=+8 mm), (c) coronal (level of the anterior commissure, Talairach y-coordinate=0 mm), and (d) axial projections of tracts in Talairach space, using center-of-mass coordinates. These tracts run through the medial orbitofrontal cortex (mOFC), central orbitofrontal cortex (cOFC), or lateral orbitofrontal cortex (IOFC); subcaudate

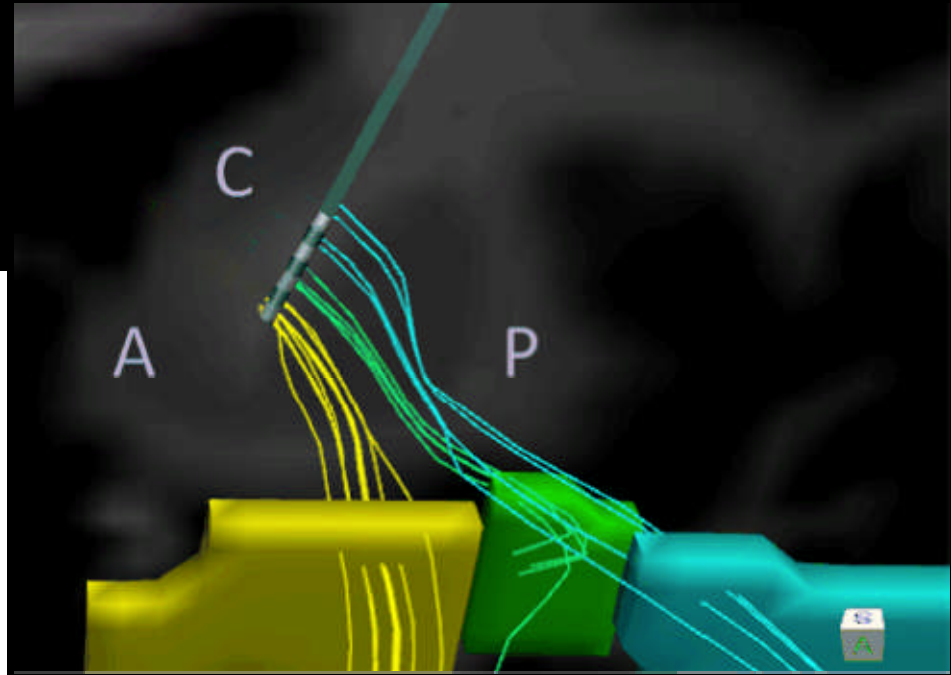
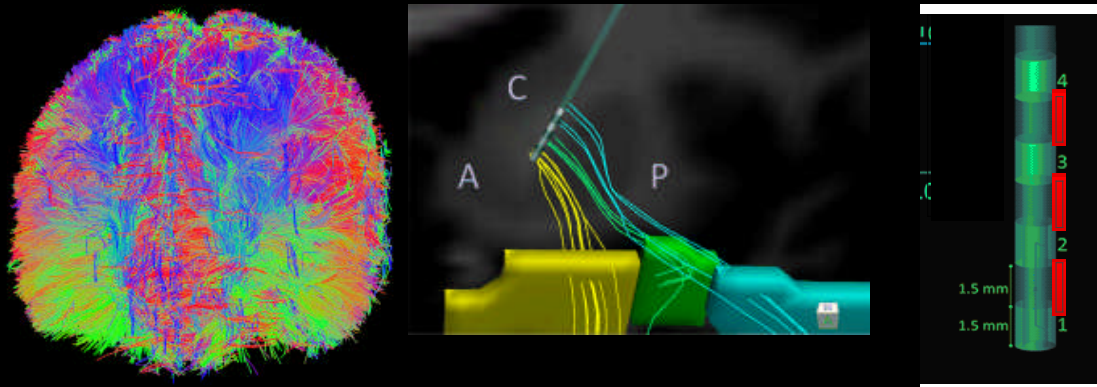
tractotomy lesion (SCT); and brainstem. Tracts: mOFC-SCT-brainstem (*blue*), cOFC-SCT-brainstem (*green*), and IOFC-SCT-brainstem (*cyan*). (e) Expanded region of brainstem of (d). The yellow region indicates the approximate area of intersection between the tracts and the axial slice. (f) 3D oblique projection of tracts in Talairach space, with a view from the dorsal aspect

## Connectome data acquisition and analysis

**Scanner:** Siemens 3 Tesla “Skyra Connectom” at the MGH A. Martinos Center for Biomedical Imaging

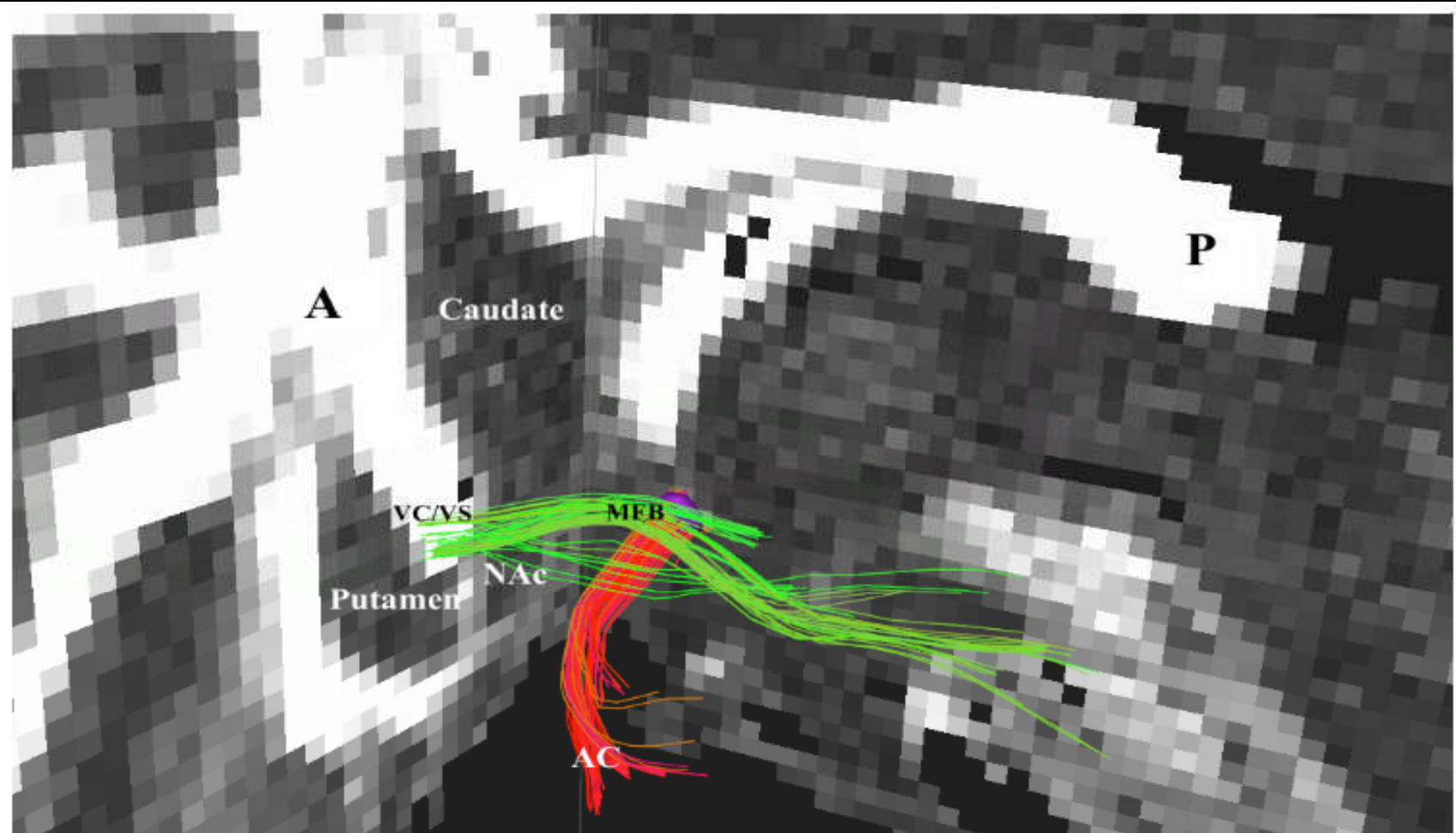
**Acquisition:** multi-shell Q-ball imaging (QBI) data with a spin-echo echo planar imaging (EPI) pulse sequence (TR= 8,800 ms, TE= 57 ms, 96 slices, 21 cm<sup>2</sup> field of view, 1.5 mm isotropic voxels, at multiple b-values of 1,000 s/mm<sup>2</sup>, 3,000 s/mm<sup>2</sup>, 5,000 s/mm<sup>2</sup> and 10,000 s/mm<sup>2</sup>).

**Analysis:** Fiber tracts were sampled using deterministic streamline tractographic analysis with TrackVis



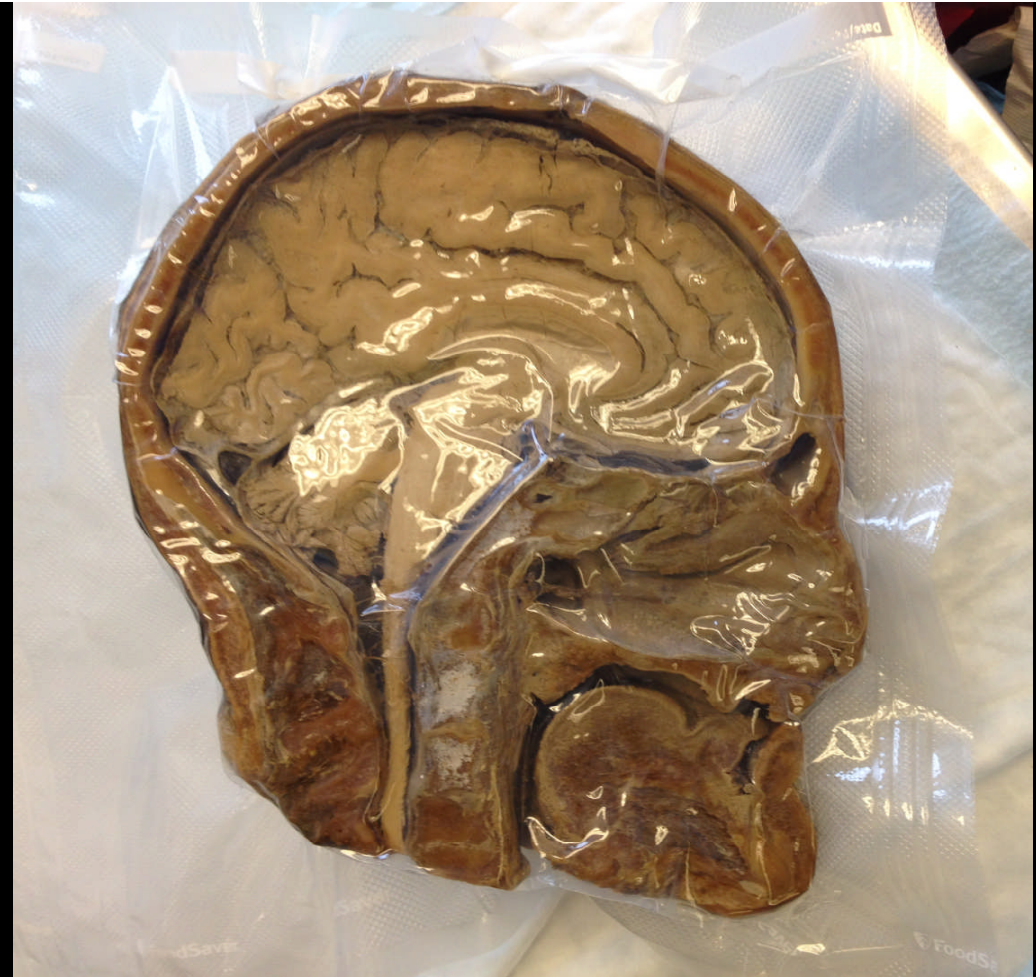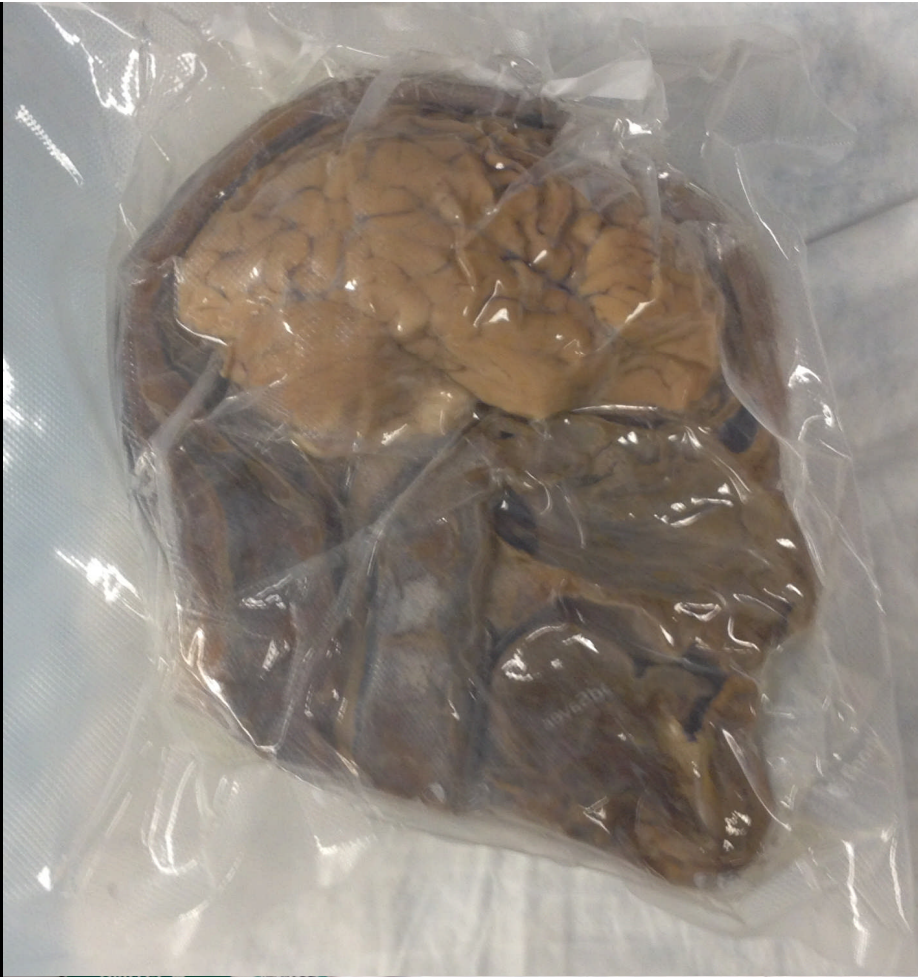**Fig. 3:** (left) DSI connectome data set, (middle) electrode placement in the VC/VS target area traversed by fibers (yellow fibers) of the ventromedial prefrontal-basal ganglia tract at the C.A.P. coronal slice. The latter fibers stem from the ventromedial prefrontal area (yellow block). (A=nucleus accumbens, C=caudate nucleus, P=putamen), and (right) electrode geometry with the proposed embedded thin solid state temperature sensor film (red).

**DBS  
in OCD  
using  
Connectome  
Technology**

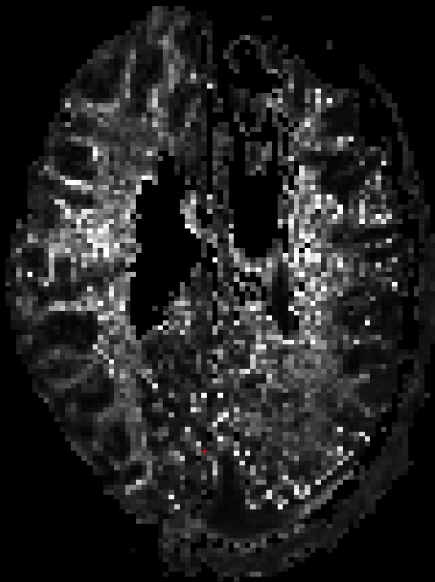


**Fig.2. Topographic relationship between the Anterior Commissure (AC) and Medial Forebrain Bundle (MFB) in an individual subject.** These data were acquired using the 3 Tesla Siemens Connectome at the A. A. Martinos Center for Biomedical Imaging at MGH. The fiber tracts were sampled and visualized using TrackVis streamline tractography. The MFB (in green) is shown in a position superior to the AC (in red). As it courses from a posterior (P) to an anterior (A) position MFB goes from the midbrain, then passes above the AC and then through the ventral capsule/ventral striatum (VC/VS) area en route to the prefrontal regions. The background of the figure consists of a midsagittal and a coronal section derived from the fractional anisotropy (FA) map of this dataset. The coronal section is at the C.A.P. (Caudate-Accumbens-Putamen) anatomical level to portray the topography of MFB within the VC/VS area above the nucleus accumbens septi (NAc).





The half-head sample sealed in a vacuumed plastic (top-right) and assembly of a right brain hemisphere opposite to the half-head sample to fill-in the head coil and prohibit image distortion (left images). The assembled half-head-half-brain sample was used for imaging



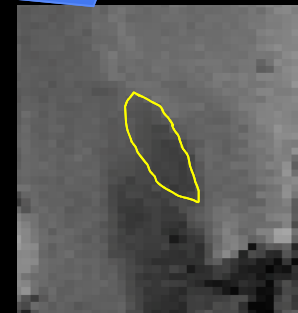
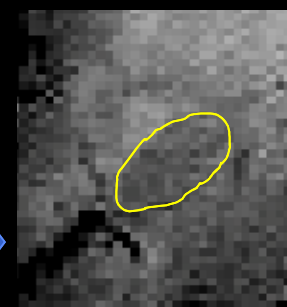
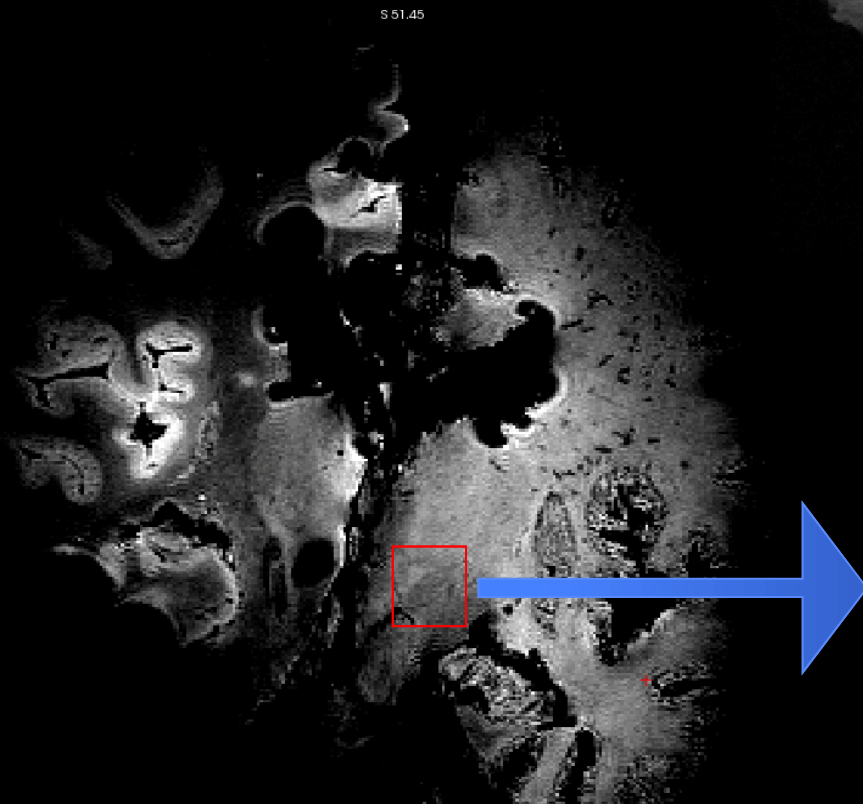
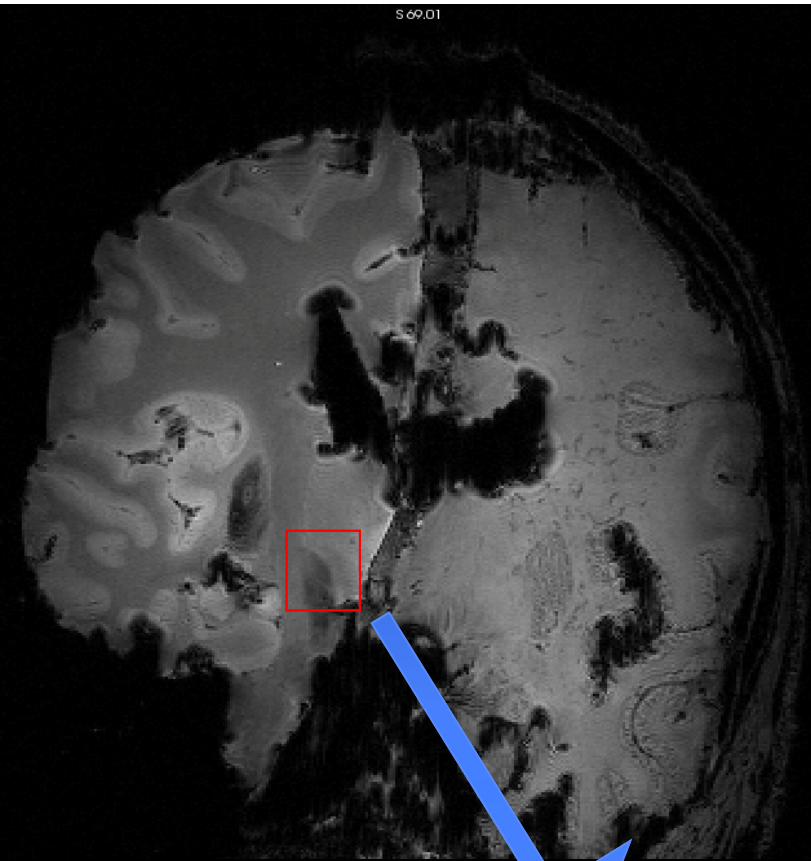
Upper-left image: Axial section of fractional anisotropy map (FA map) of the head sample obtained by Q-ball diffusion imaging

Connectome Scanner @ Martinos Center for Biomedical Imaging;  
Sequence: 64 dir Q-ball imaging

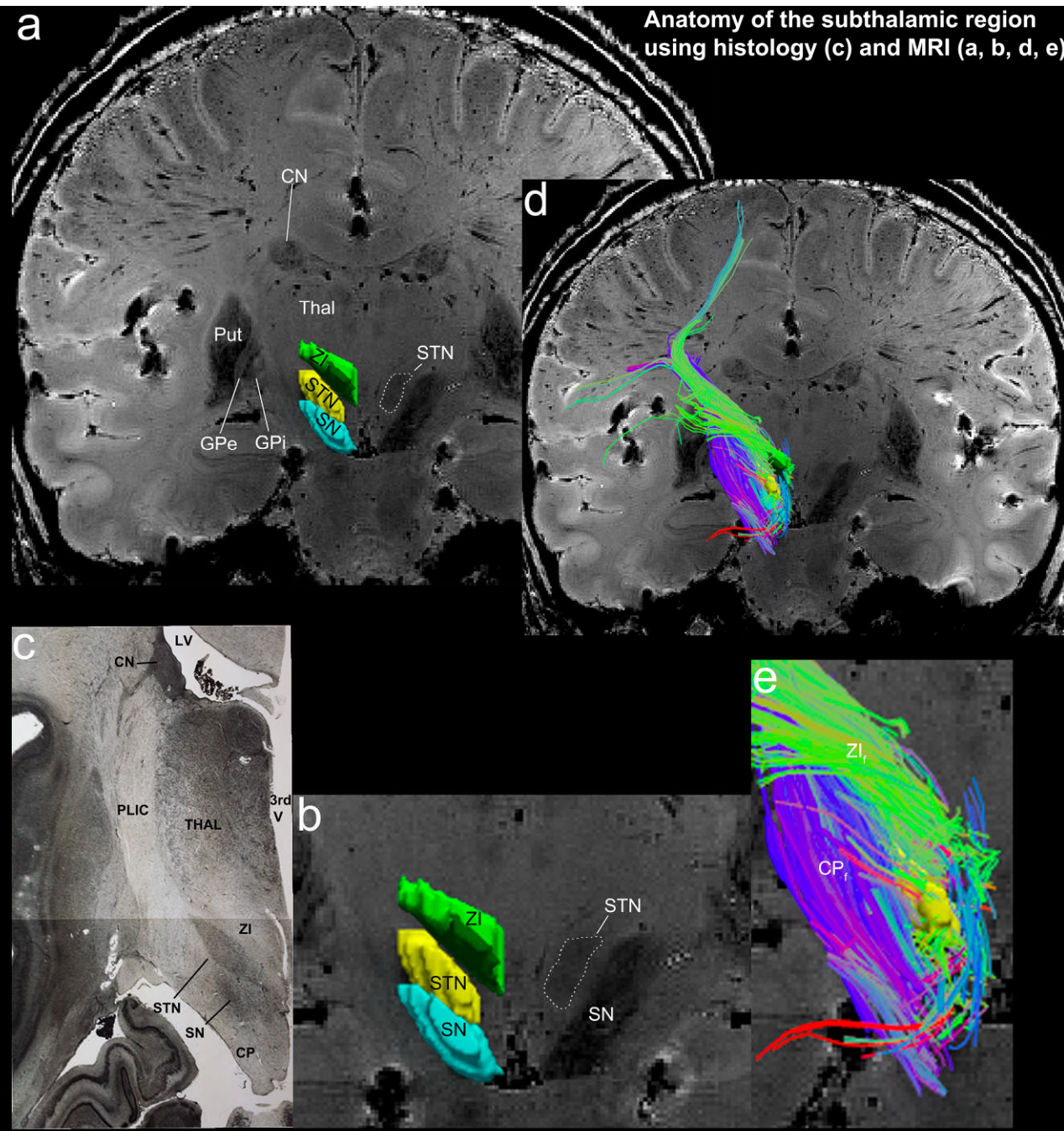
Voxel size: 1.5 mm isotropic  
Total time: 11mins 44s  
TR: 8800 ms; TE: 57.0 ms  
Echo spacing: 0.63 ms  
Number of directions: 64  
b-value: 1400  
PAT: 3; Fat suppression: strong

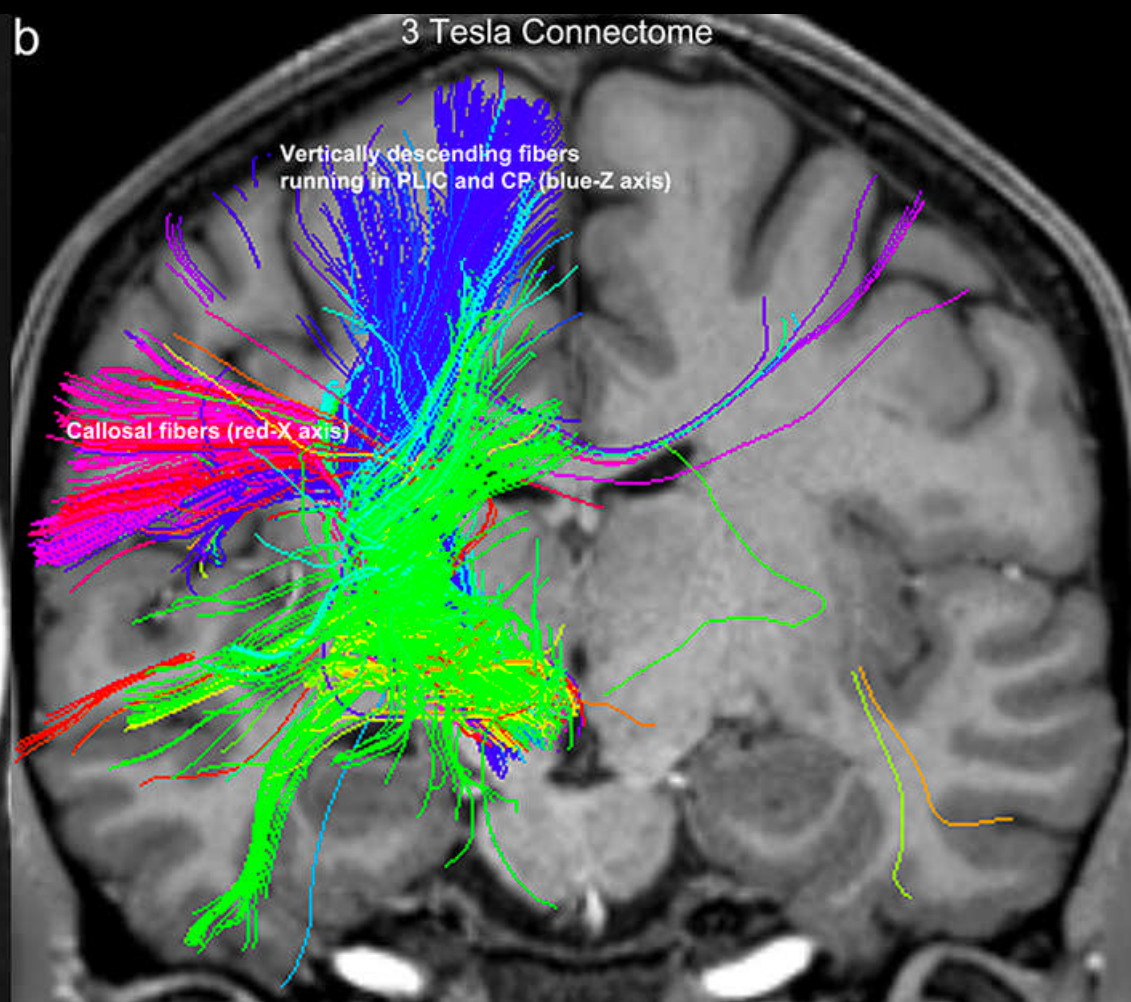
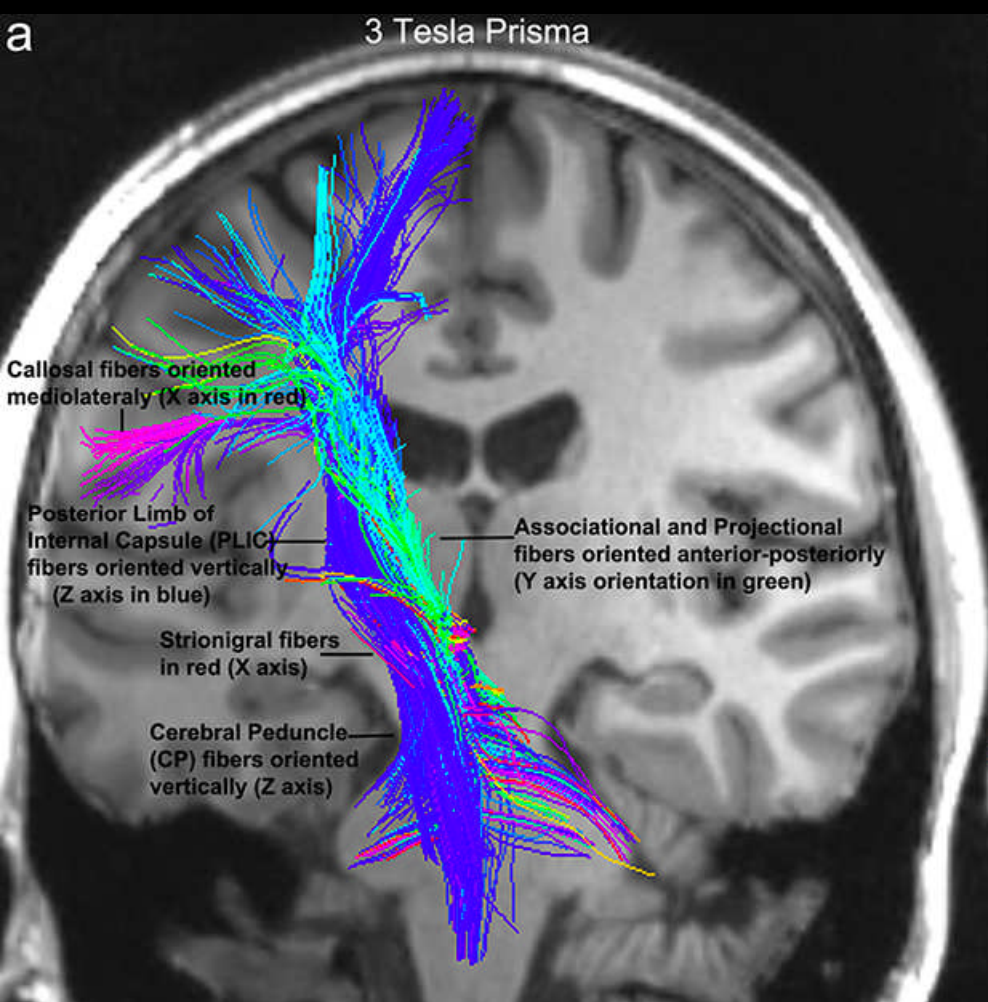
Upper-right and bottom images: Coronal sections of high-resolution structural MRI of right (upper-right image) and left (bottom image) subthalamic nucleus (STN); lower-right images: outlined zoomed versions of STN.

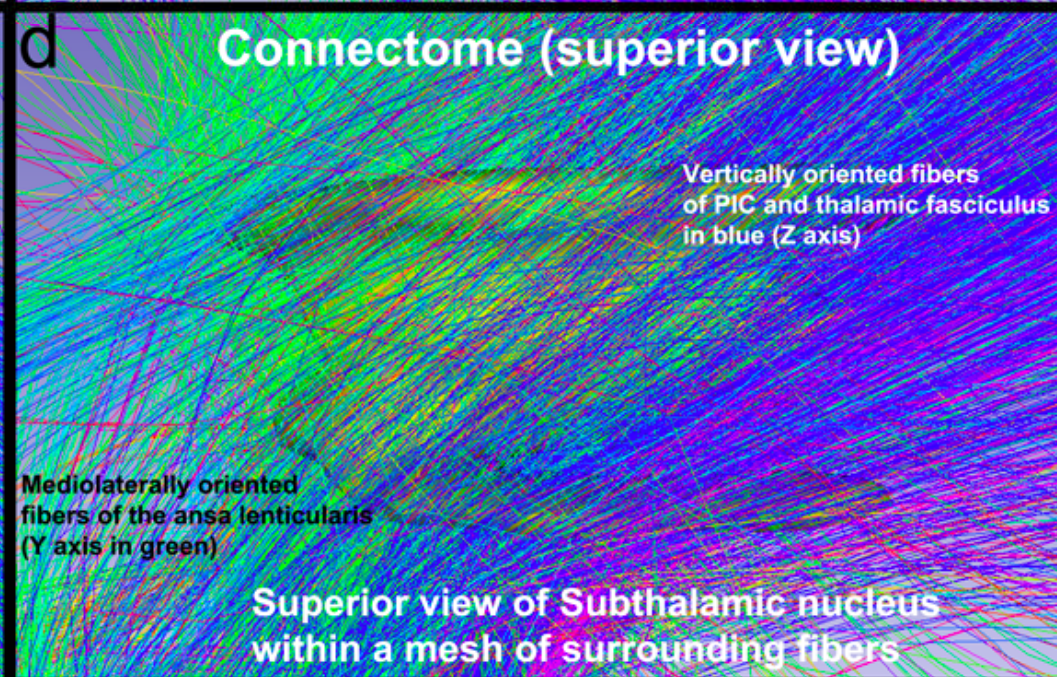
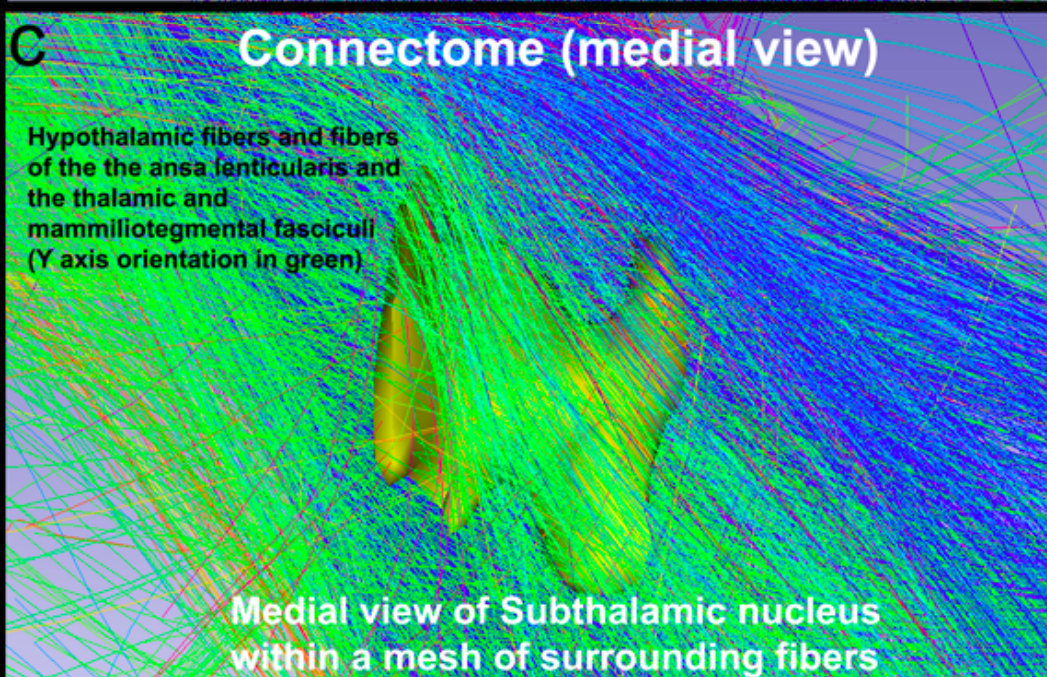

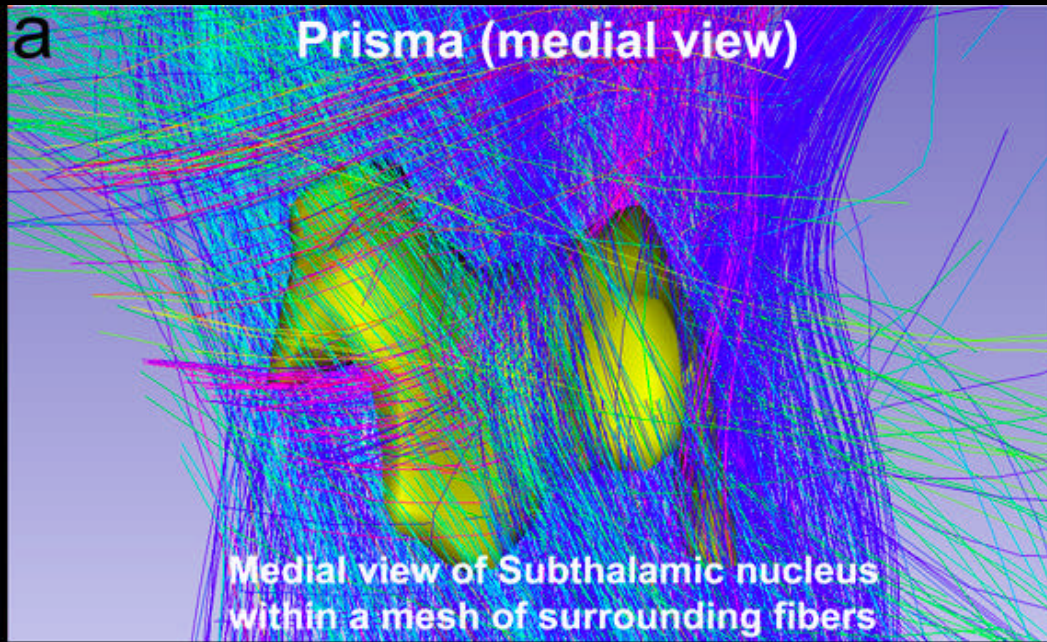
7 Tesla Scanner @ Martinos Center for Biomedical Imaging; Sequence: FLASH;  
Voxel size: 400um isotropic; Total time: 1:09:08  
TR: 23 ms; TE: 10.2 ms; Echo spacing: 10 ms  
Flip Angle: 30.0 degrees; PAT: off, Fat supp: off



Anatomy of the subthalamic region using histology (c) and MRI (a, b, d, e)

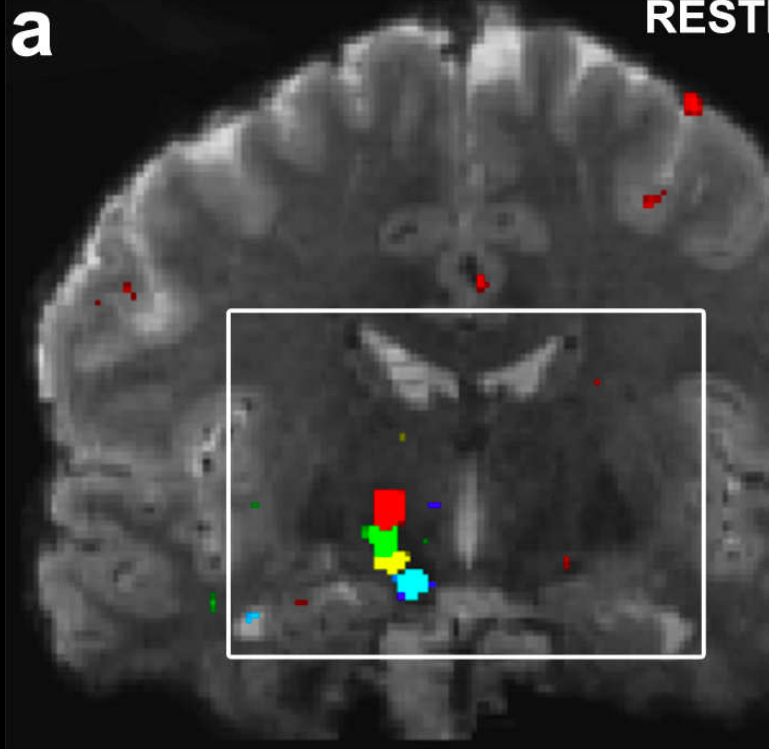




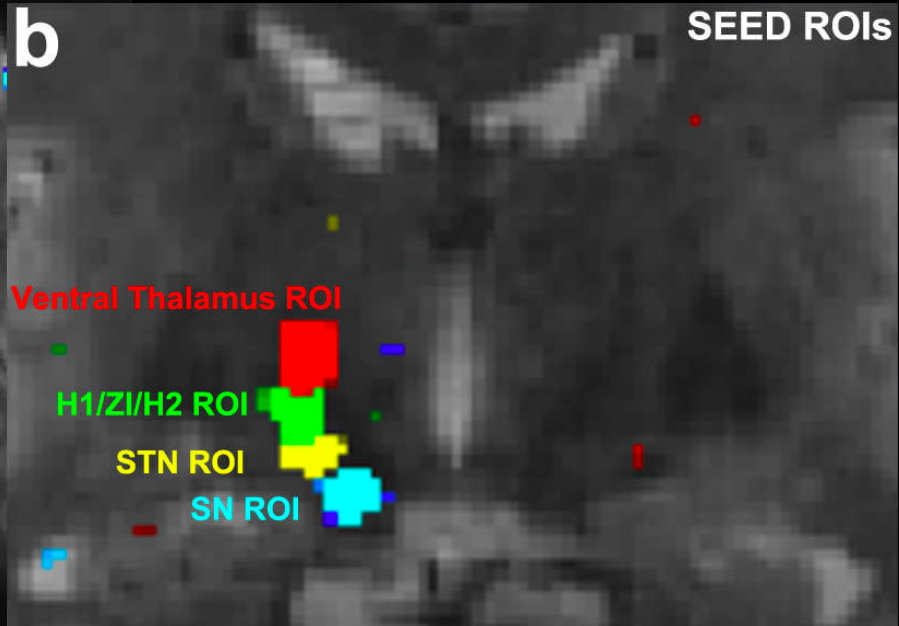


# RESTING STATE FUNCTIONAL CONNECTIVITY

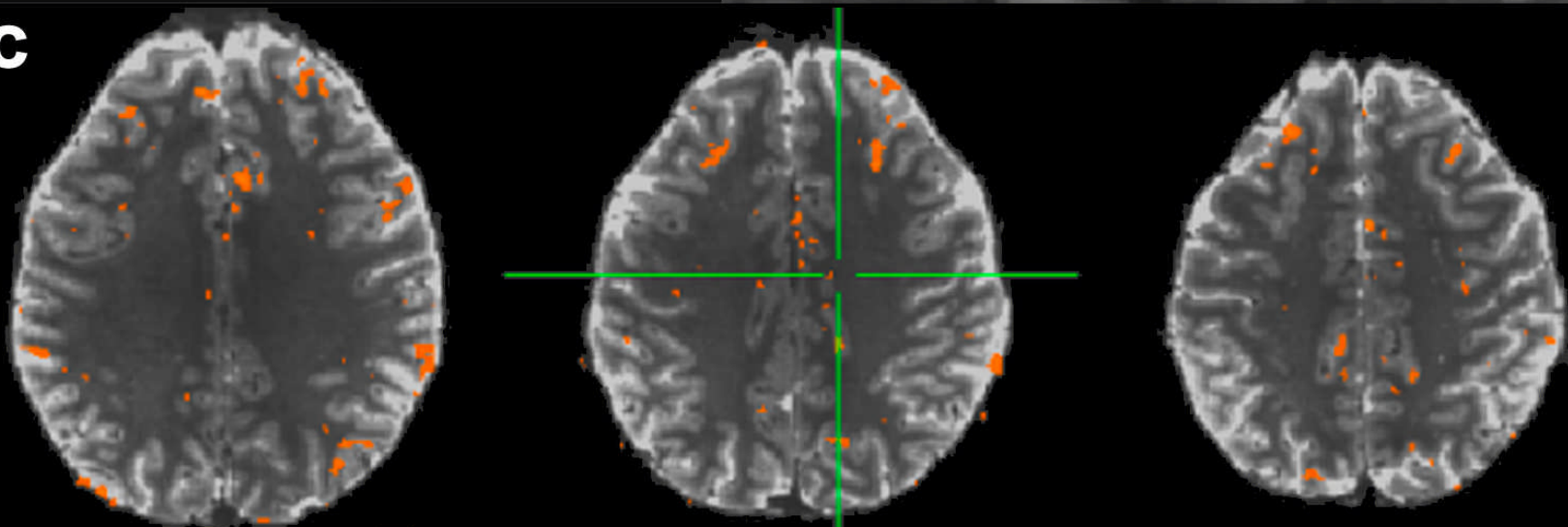
**a**



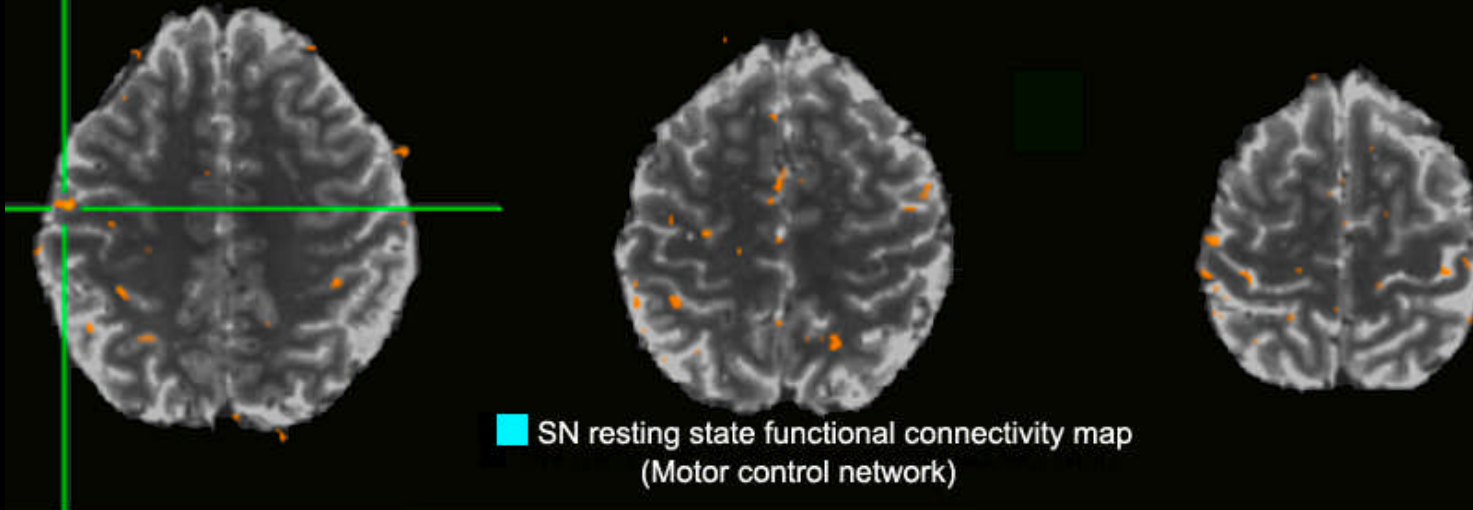
**b**




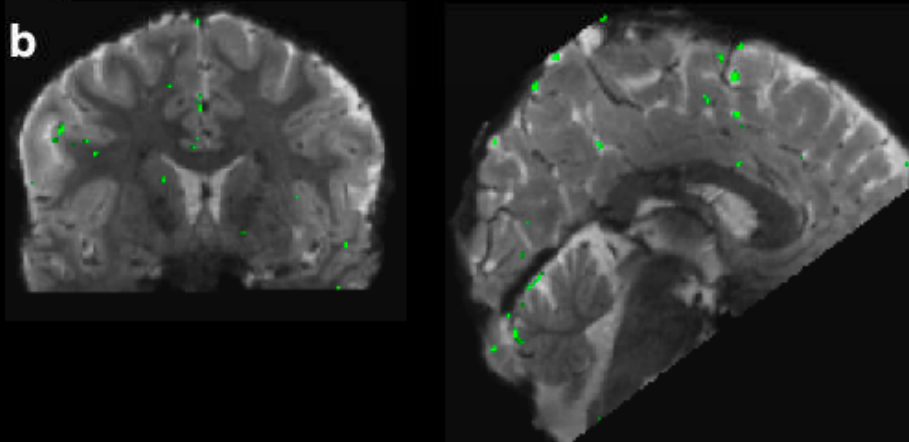
**c**



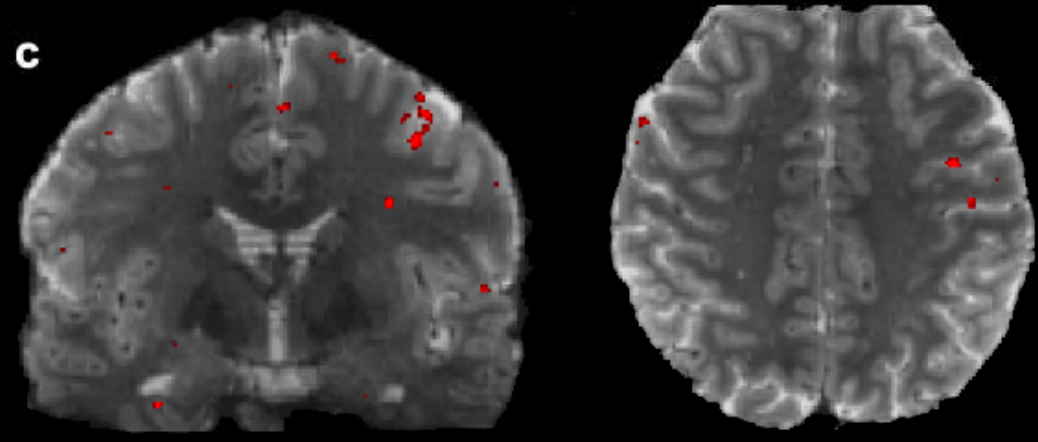
■ STN resting state functional connectivity map  
(Frontoparietal executive control network)

**a**

■ SN resting state functional connectivity map  
(Motor control network)

**b**

■ H1/H2/ZI resting state functional connectivity map  
(Episodic memory/Default-mode system)

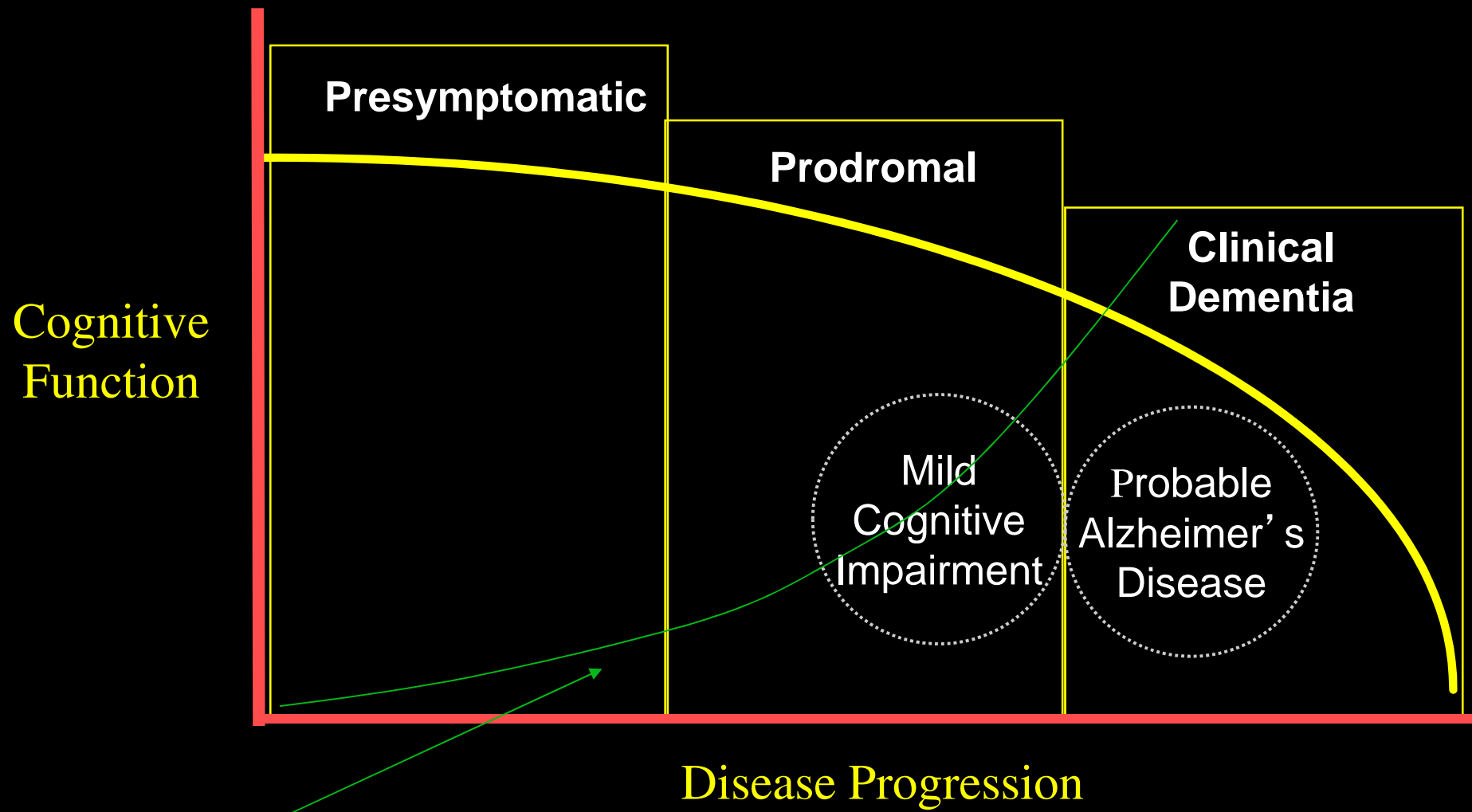
**c**

■ VM Thalamus resting state functional connectivity map  
(Sensorimotor network)

# Neurodegeneration

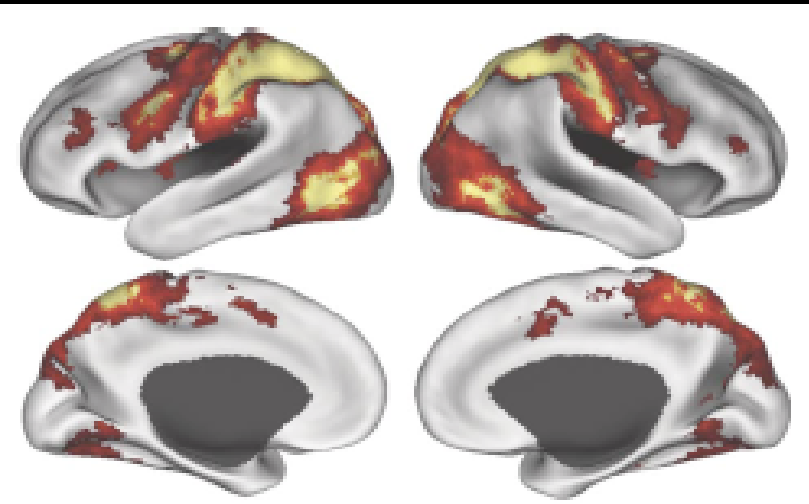


# Progression of Alzheimer's Disease: similar model for many other diseases



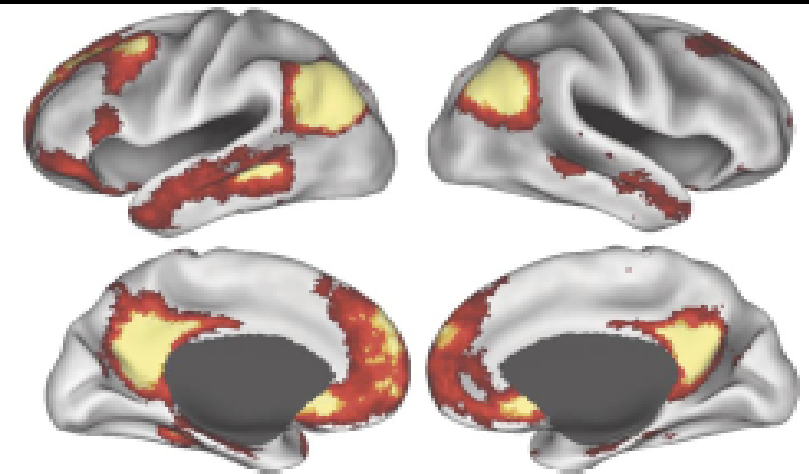
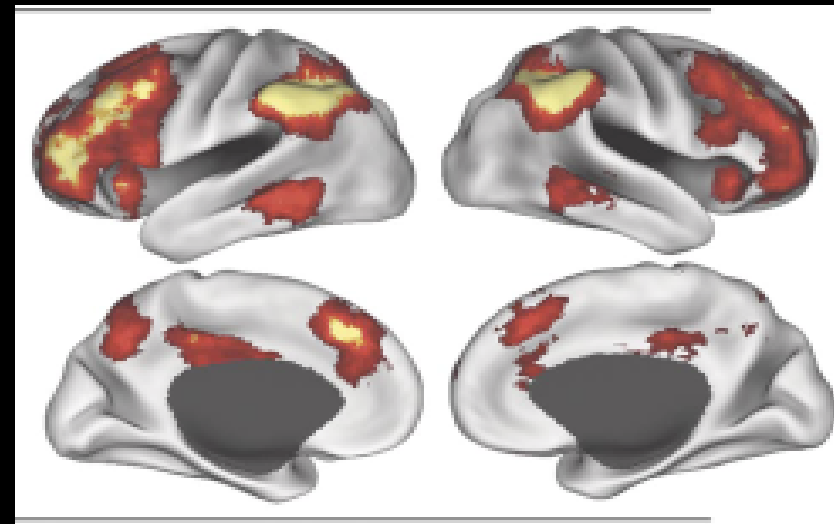
Accumulating pathology

# Large-scale cognitive systems understood through resting state fMRI



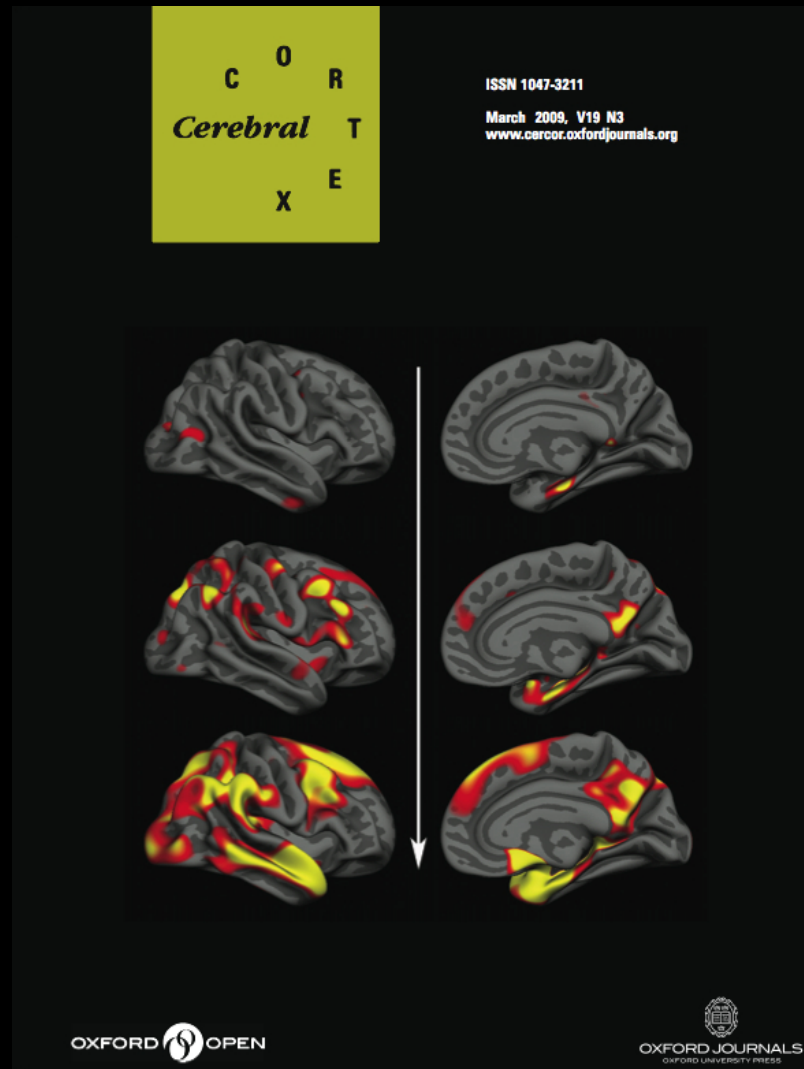
Dorsal visuospatial attention system

Frontoparietal executive control system



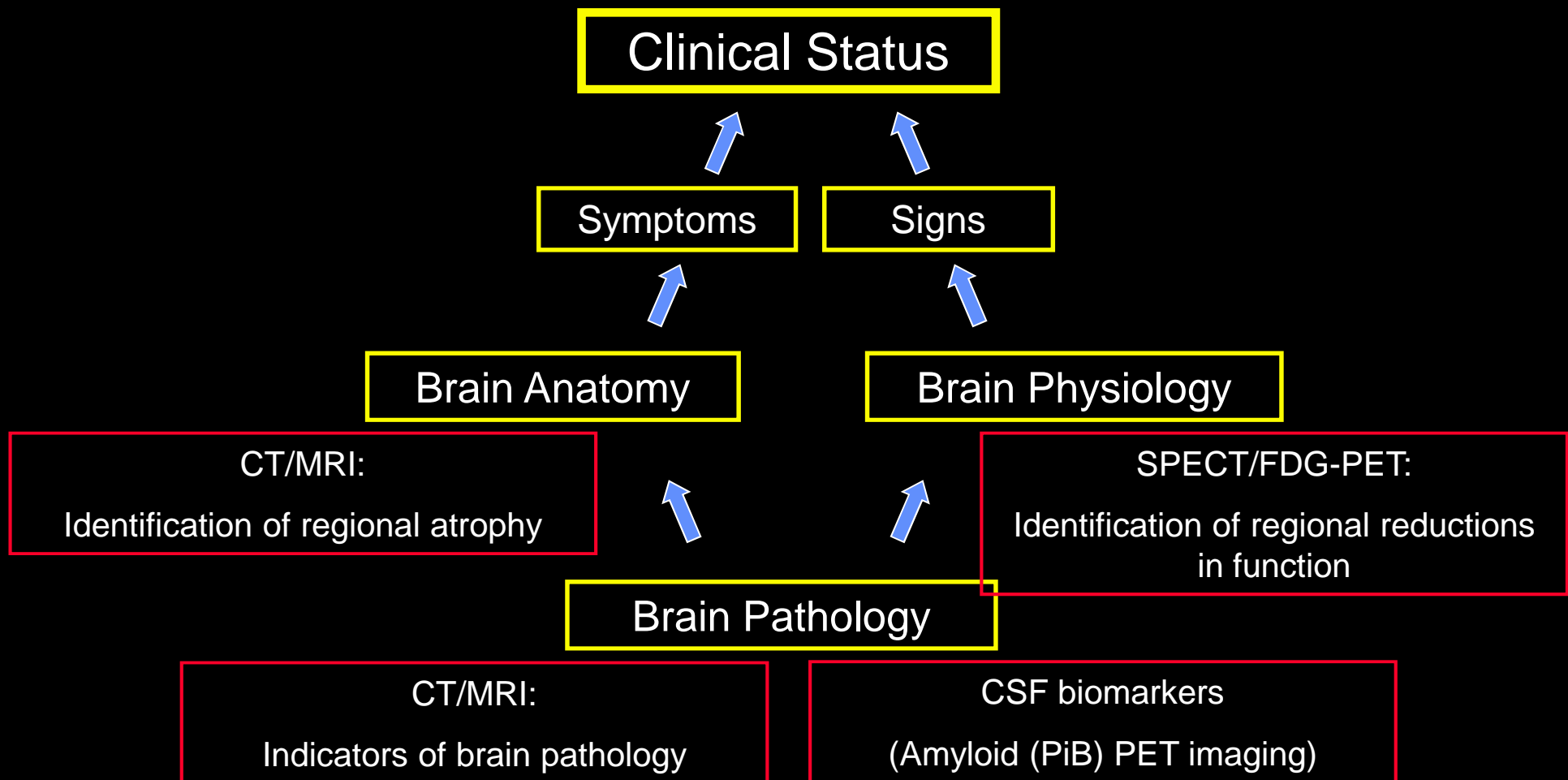
Episodic memory/Default-mode system

# AD cortical signature: Cortical atrophy compared to normals



Dickerson et al, *Cerebral Cortex* 2009

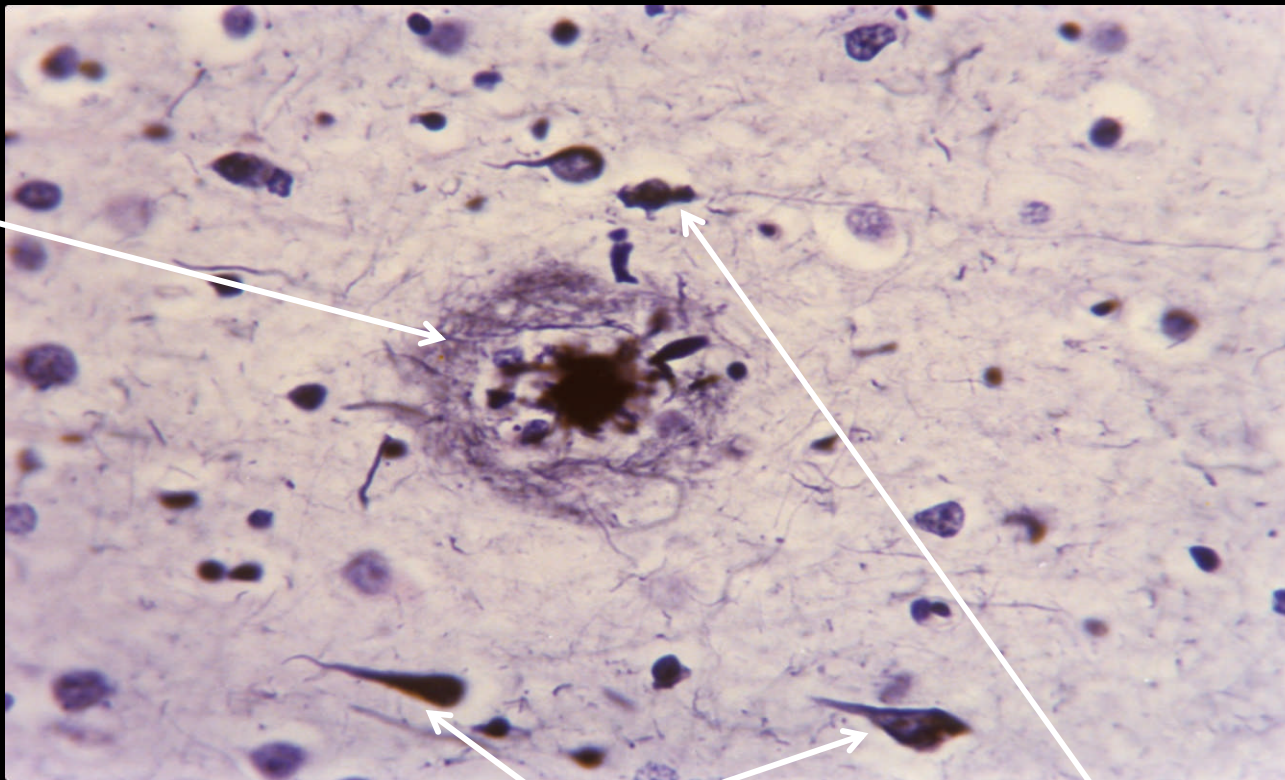
# Roles of biomarkers in dementia: Clinical practice, 2014



# Plaque and Tangles

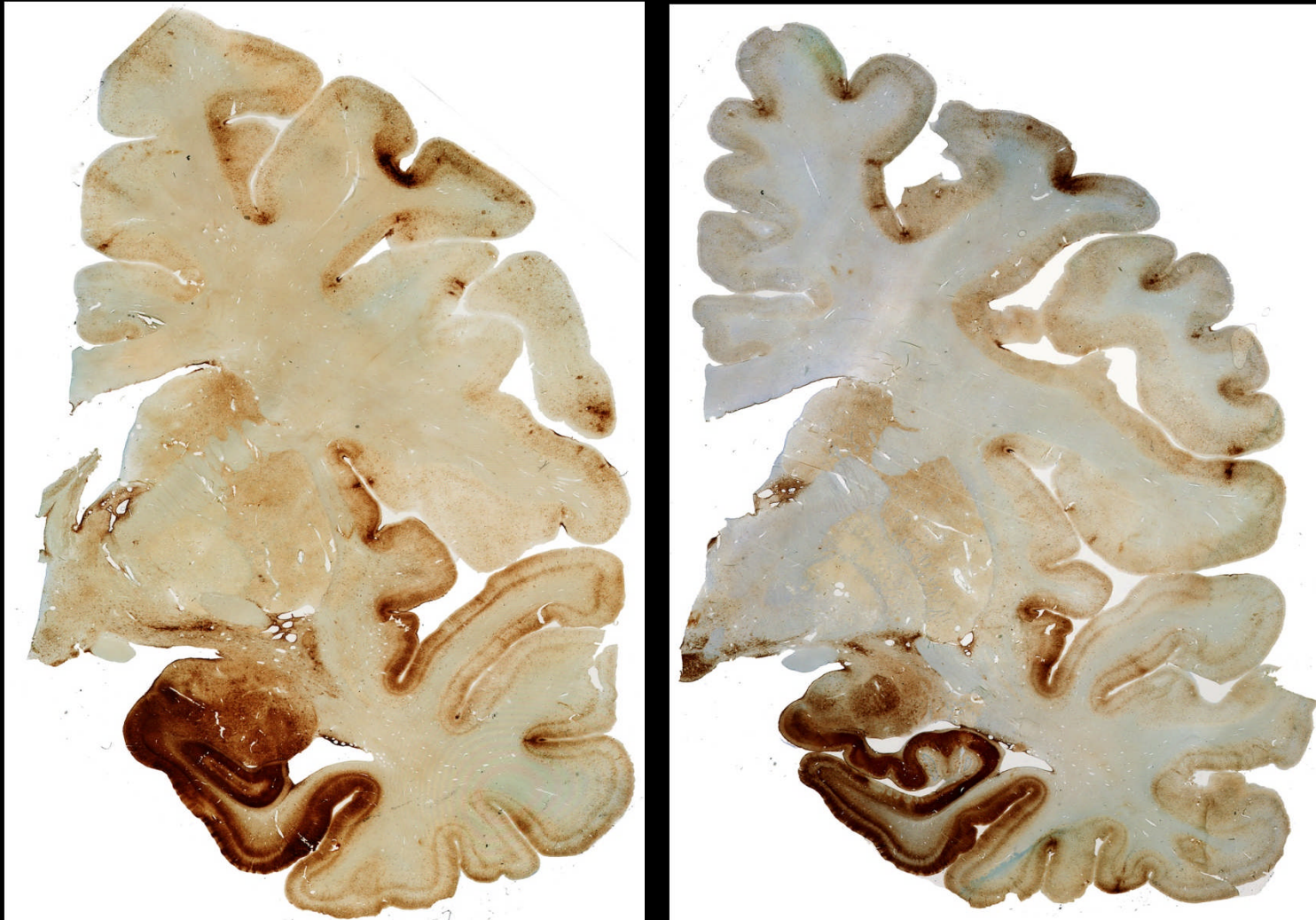
(Bielschowsky silver stain, association cortex of the temporal lobe)

Neuritic  
plaque



Neurofibrillary tangles, in neurons and as tomb-stones,  
where neurons used to be

# Only Post-Mortem Tau Pathology

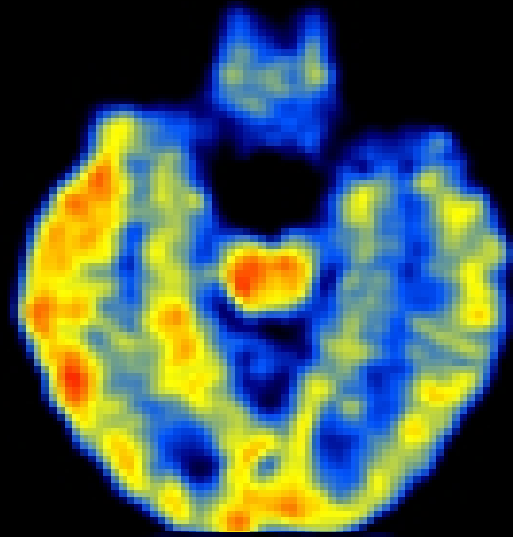
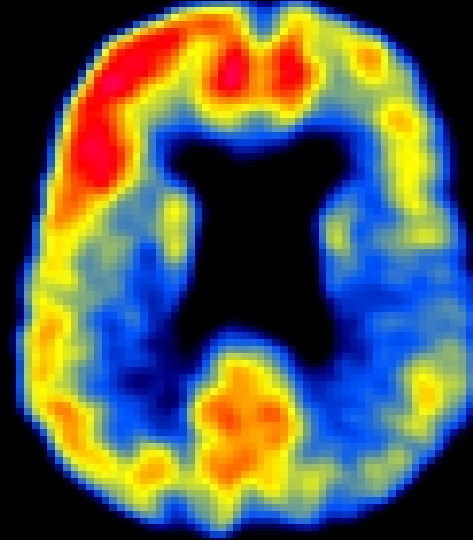


(McKee et al., 2009)

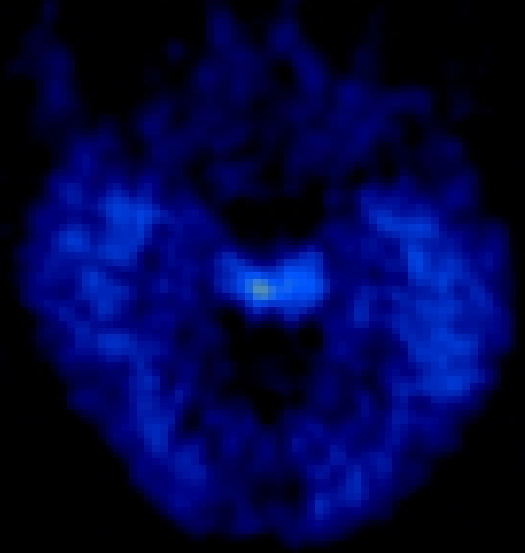
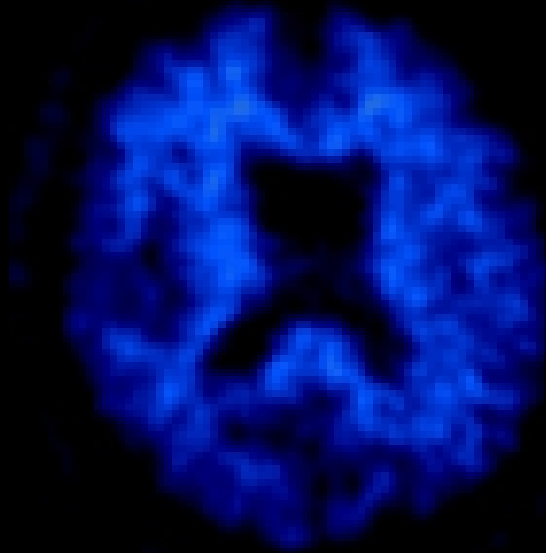
# Amyloid imaging with PET

Pittsburgh Compound-B (PiB)

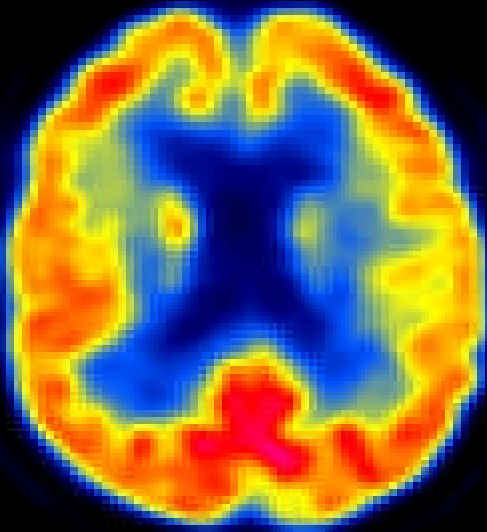
*Alzheimer's  
disease*



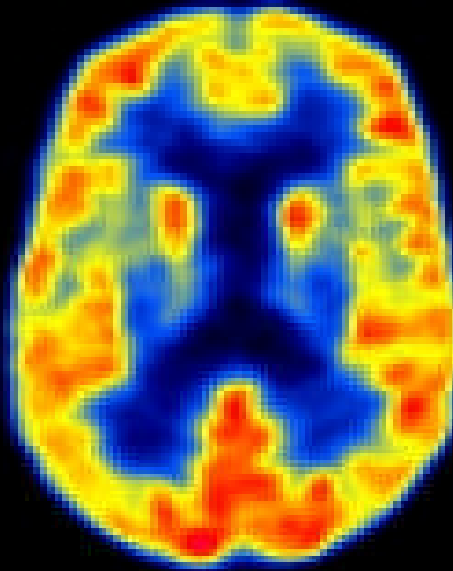
*Normal  
aging*



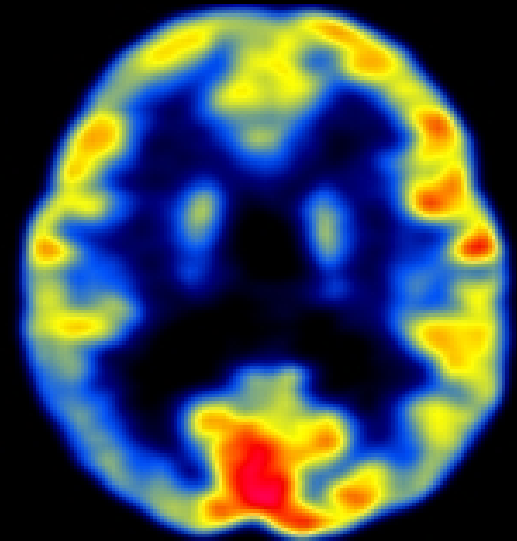
# Aging, MCI, AD: FDG-PET



**Cognitively intact  
older adult**



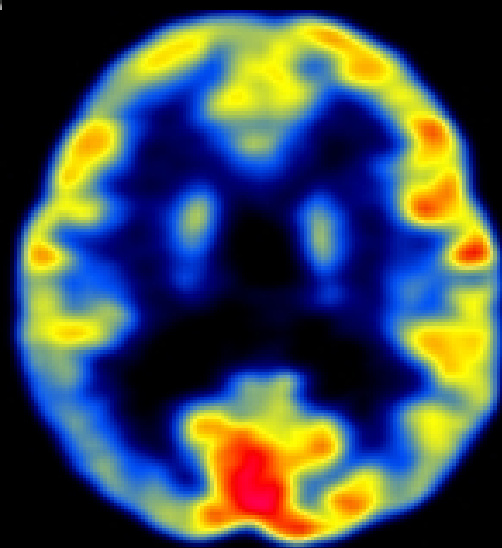
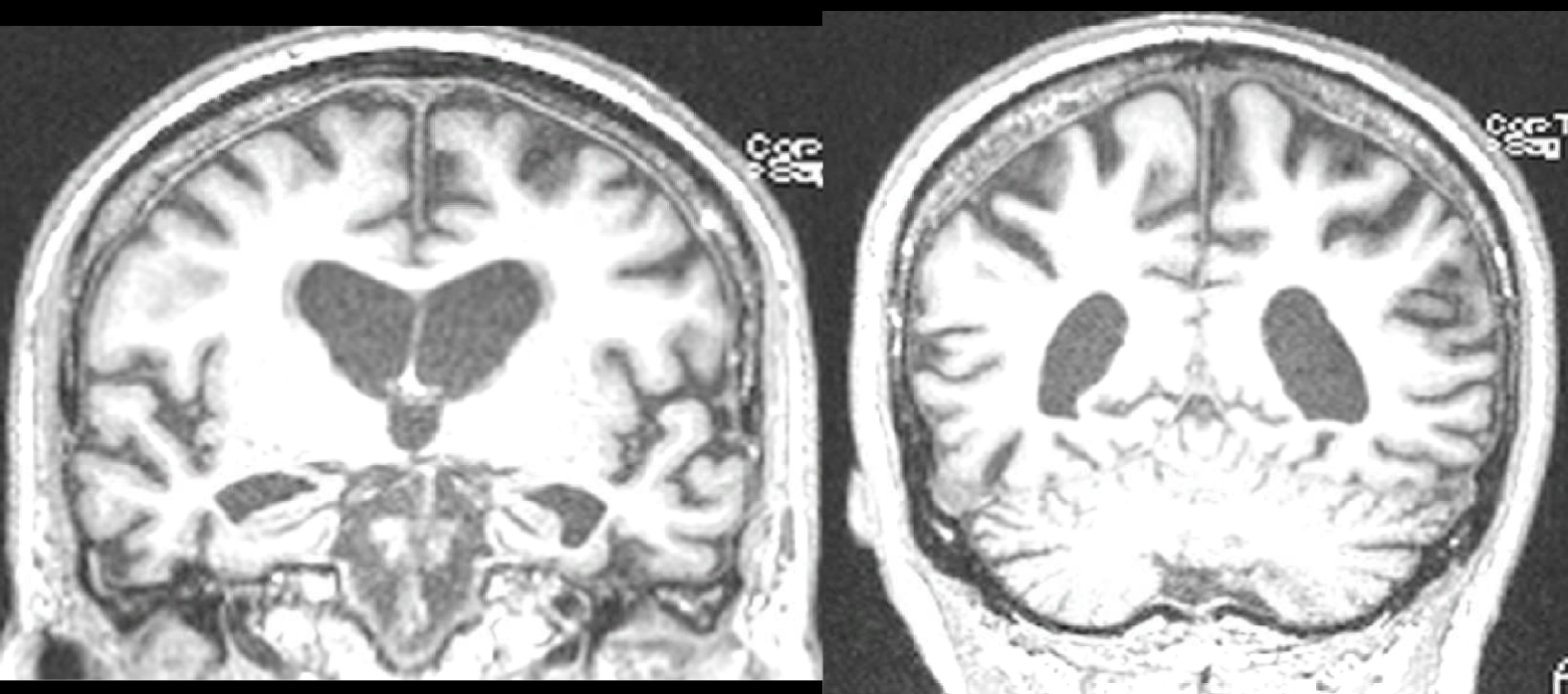
**Mild Cognitive  
Impairment**



**Alzheimer's  
Disease**



# Case 1

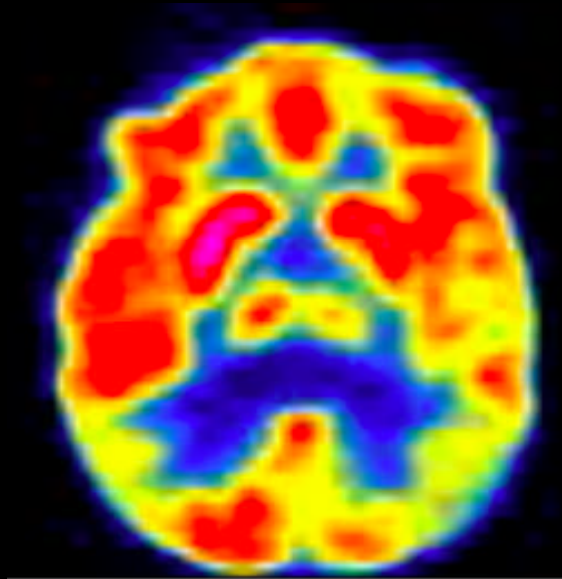
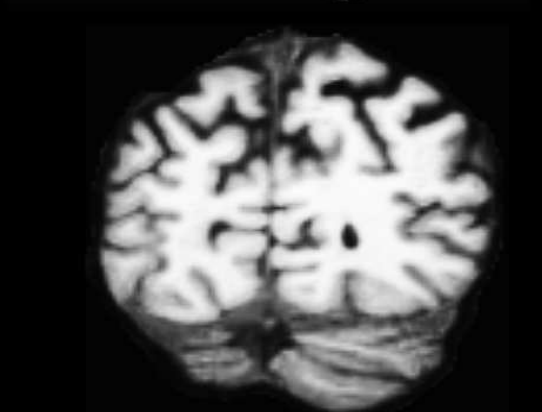
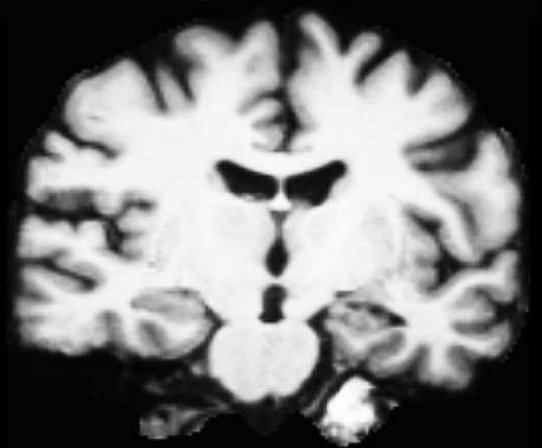
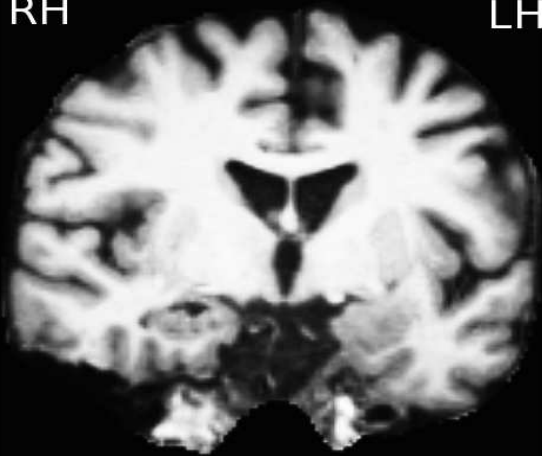


FDG-PET

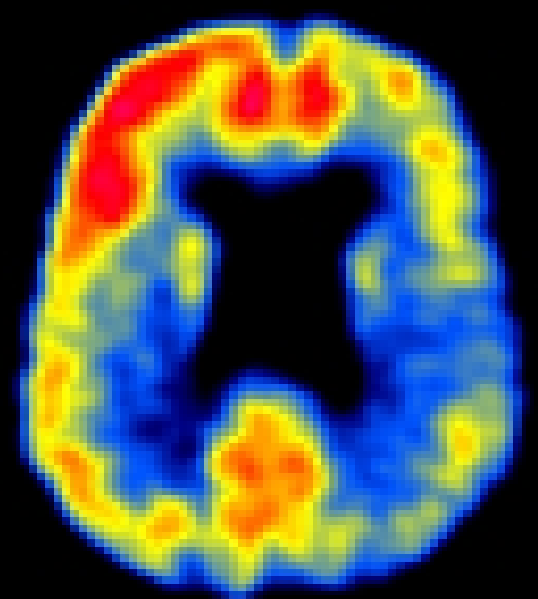
RH

LH

# Case 2



FDG-PET



Amyloid (PiB)-  
PET

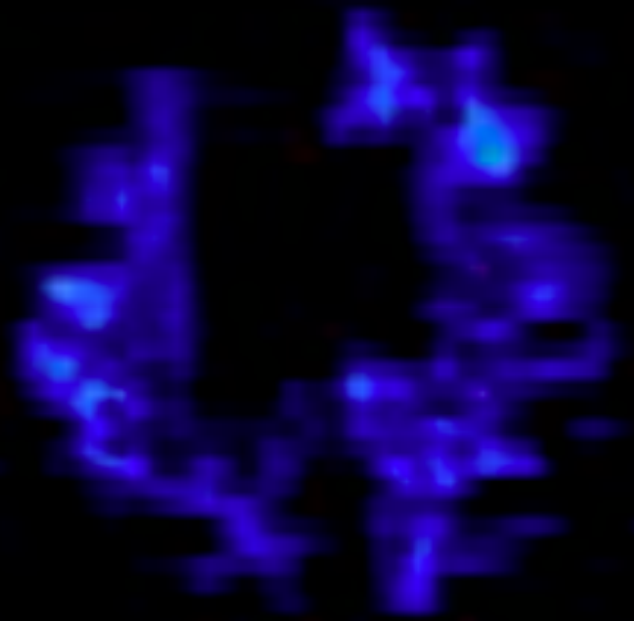
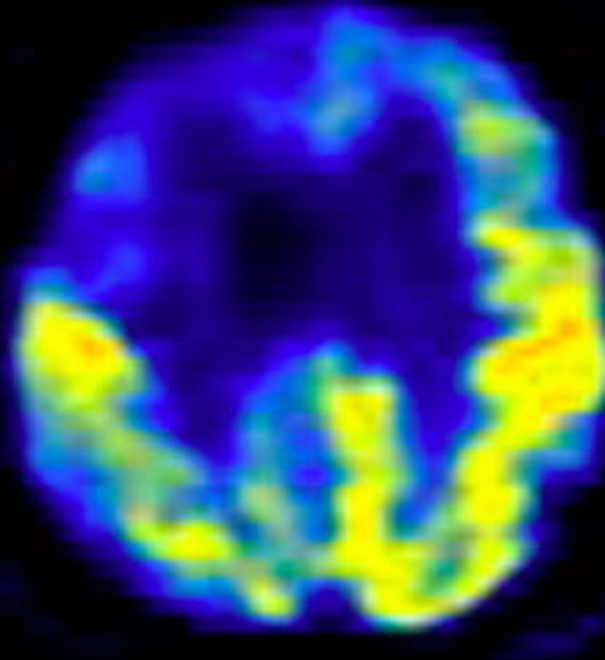
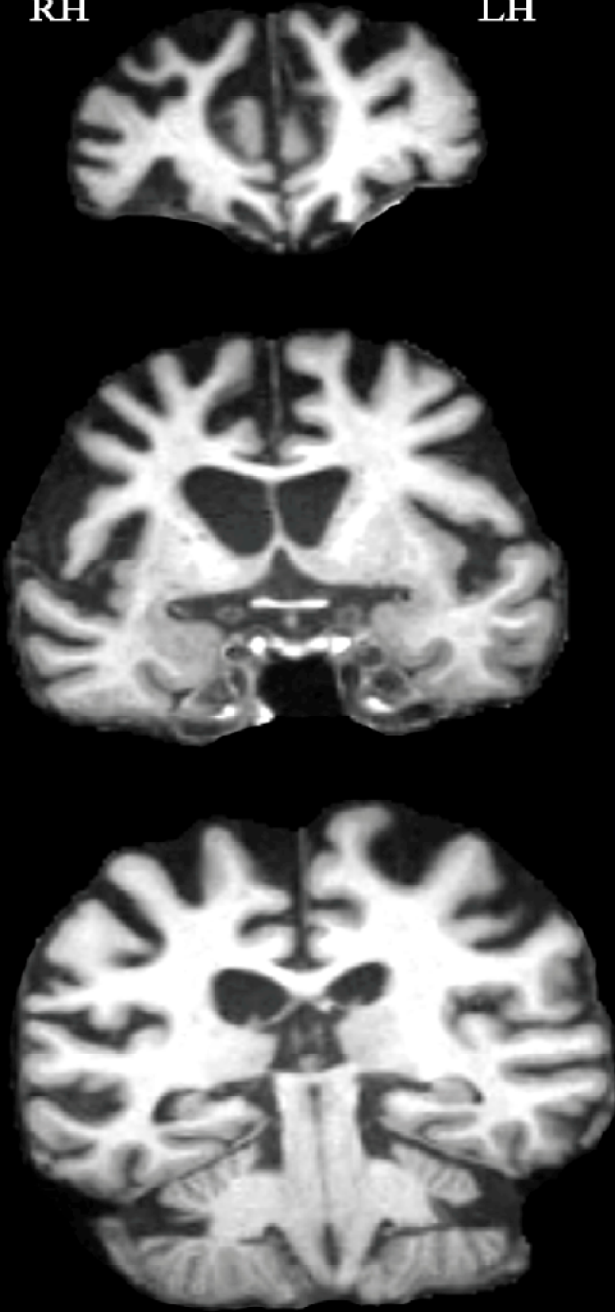
RH

LH

# Case 3

FDG-PET

PiB-PET



# Pre-Clinical PET Tracer Used in Animals

Journal of Alzheimer's Disease 31 (2012) 1–12  
DOI 10.3233/JAD-2012-120712  
IOS Press

## A Highly Selective and Specific PET Tracer for Imaging of Tau Pathologies

Wei Zhang, Janna Arteaga, Daniel K. Cashion, Gang Chen, Umesh Gangadharmath,  
Luis F. Gomez, Dhanalakshmi Kasi, Chung Lam, Qianwa Liang, Changhui Liu, Vani P. Mocharla,  
Fanrong Mu, Anjana Sinha, A. Katrin Szardenings, Eric Wang, Joseph C. Walsh, Chunfang Xia,  
Chul Yu, Tieming Zhao and Hartmuth C. Kolb\*  
*Siemens Molecular Imaging, Inc., Culver City, CA, USA*

# Next Step PET in Humans

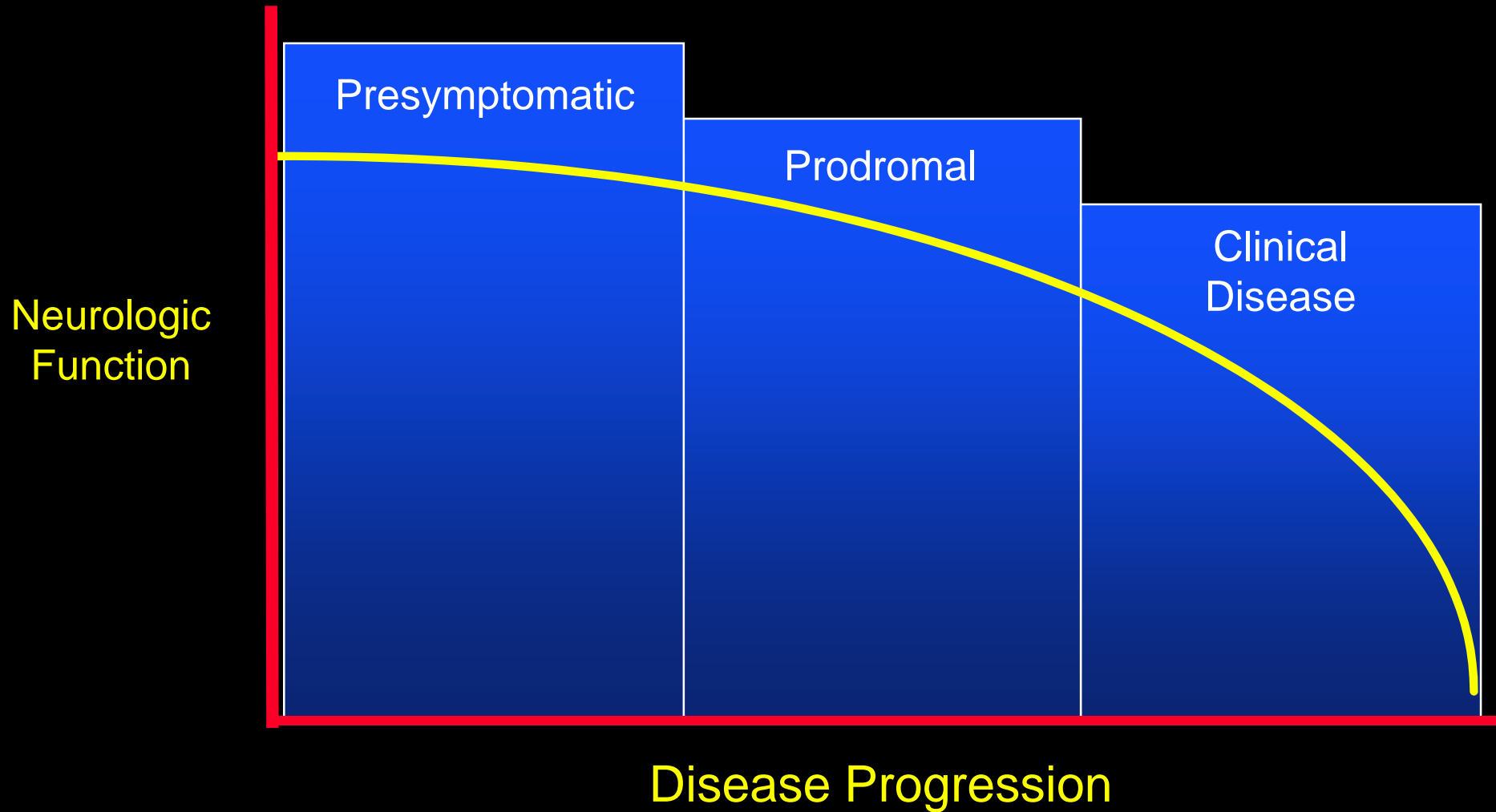
- Rule out Alzheimer's Disease (AD) in suspected CTE.
- Rule in Tauopathy in CTE – the Holy Grail. Positive *in vivo* tau imaging (paired helical filament Tau) using new PET Tau ligand from Siemens.
- Predictions: Amyloid-Beta retention in AD, but not CTE or controls (PiB), and Tau retention in AD and CTE but not controls (Tau; see table, below).

	AD	CTE	Control
PiB	+	-	-
Tau	+	+	-

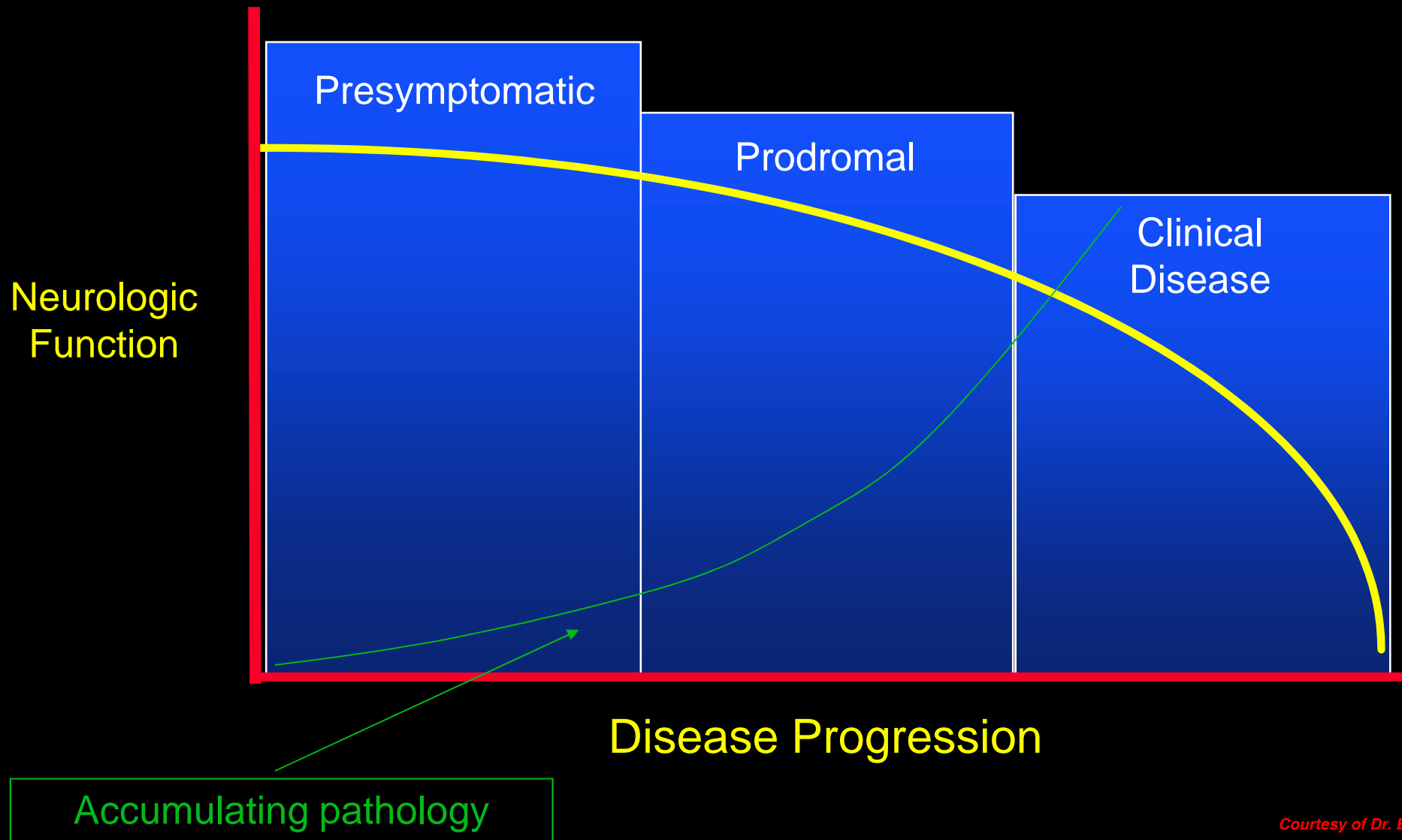
Imaging technology is not just making pretty pictures or even simply increasing our scientific understanding of Alzheimer's and related diseases; it is in fact enabling new revolutions in testing treatments that may lead to real benefits for patients, possibly even forms of prevention.

e.g., anti-amyloid treatment with monoclonal antibodies in mildly symptomatic patients (MCI) or even asymptomatic individuals with brain amyloid.

# Progression of neurodegenerative diseases

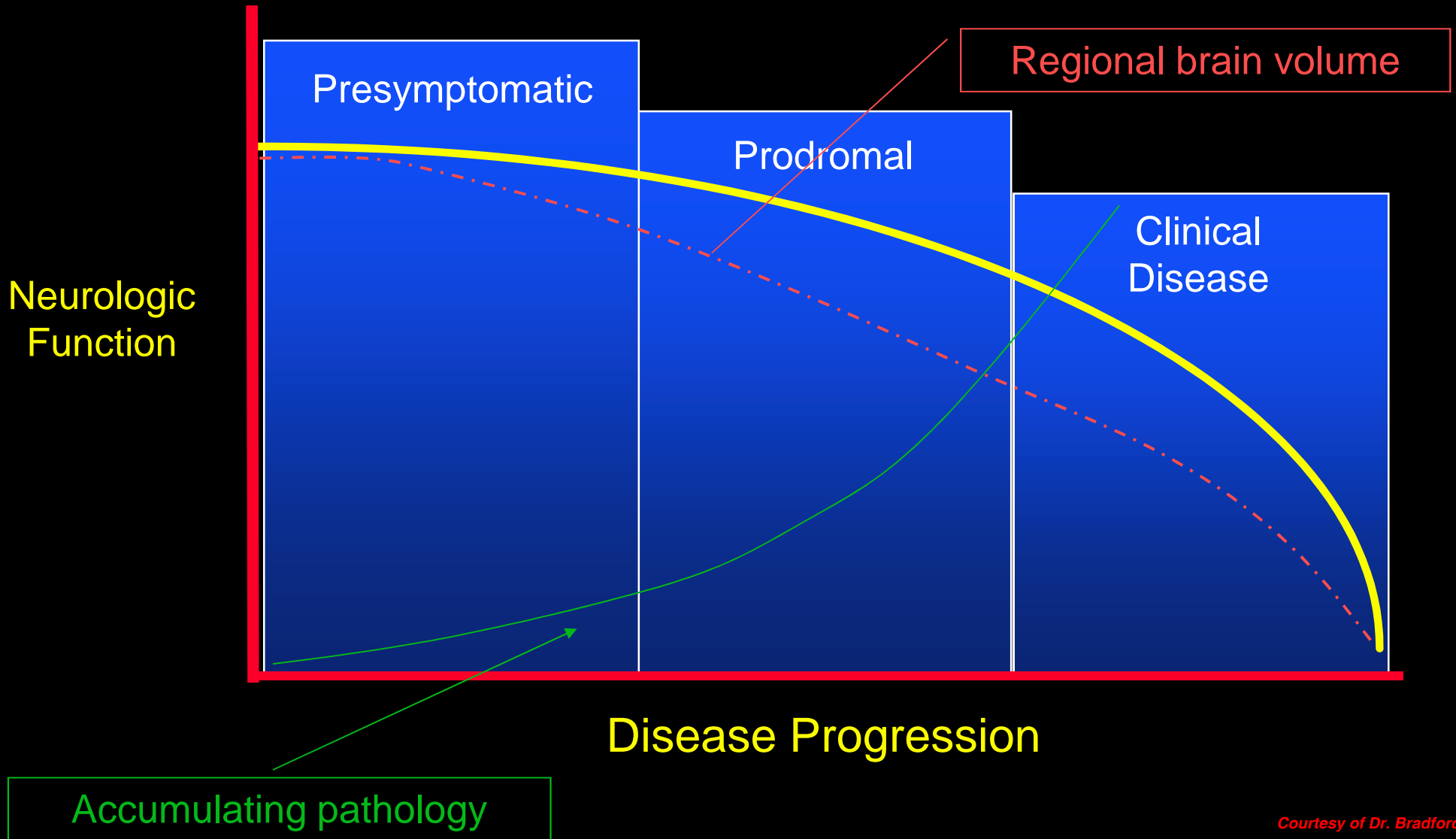


# Progression of neurodegenerative diseases

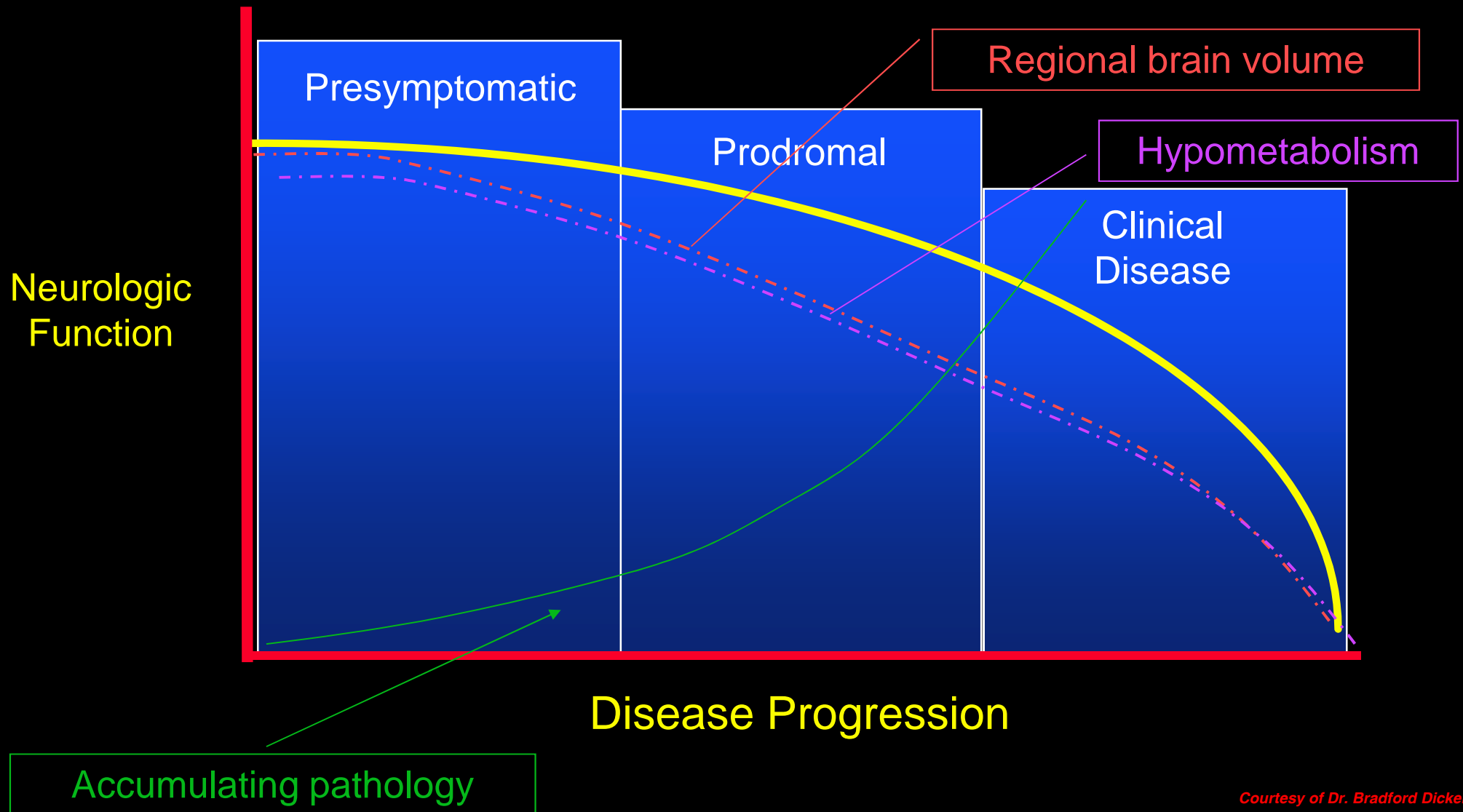




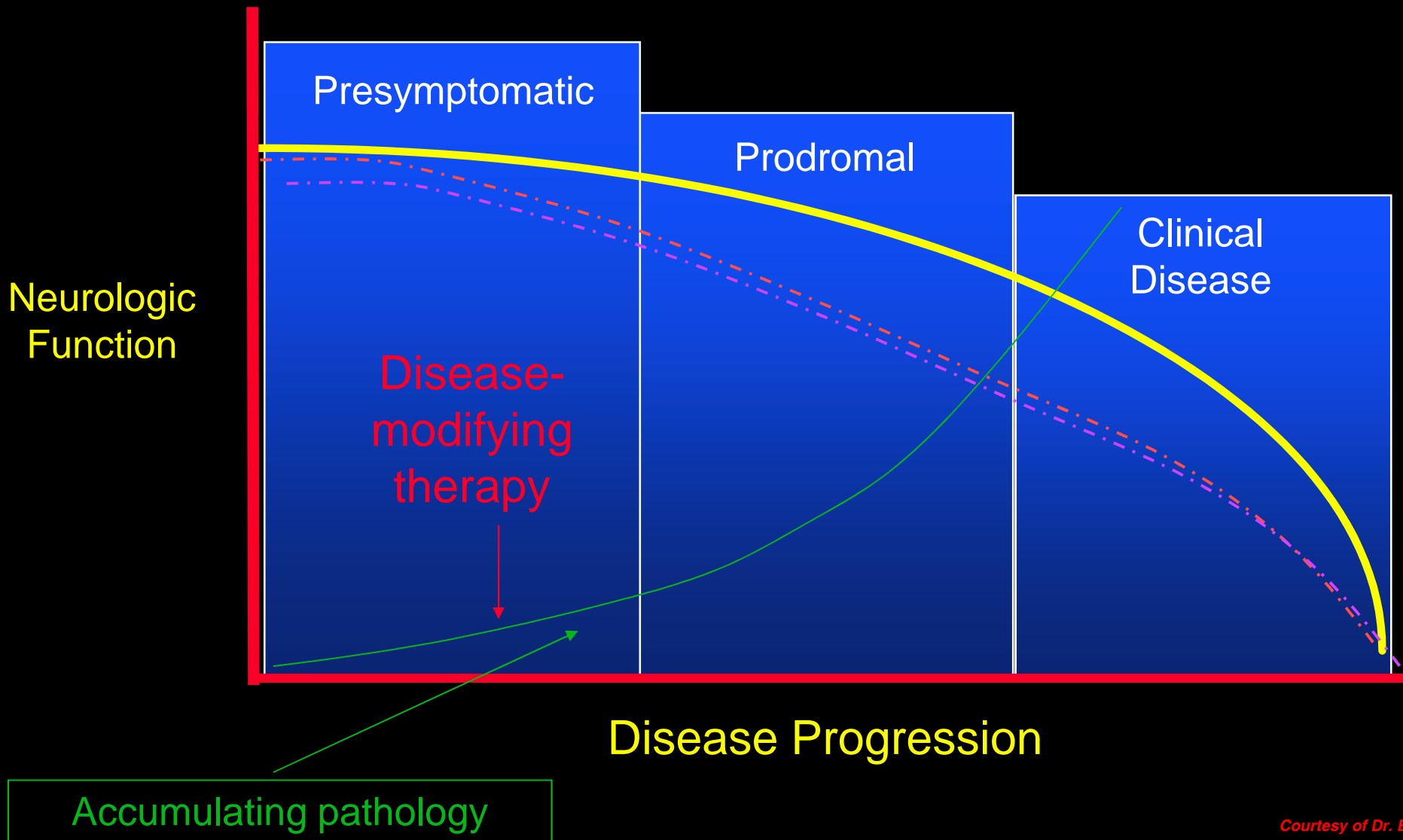
# Progression of neurodegenerative diseases



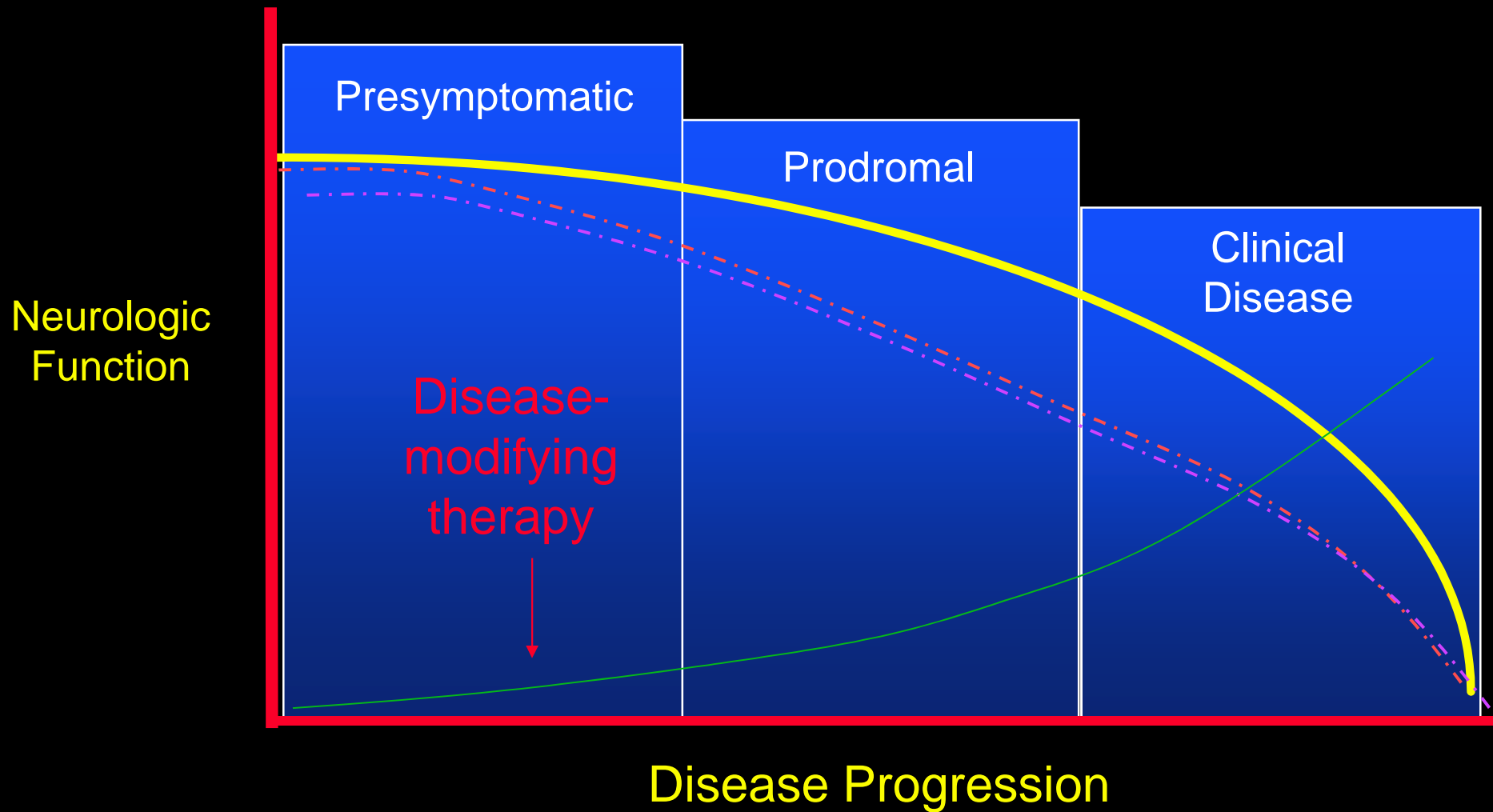
# Progression of neurodegenerative diseases



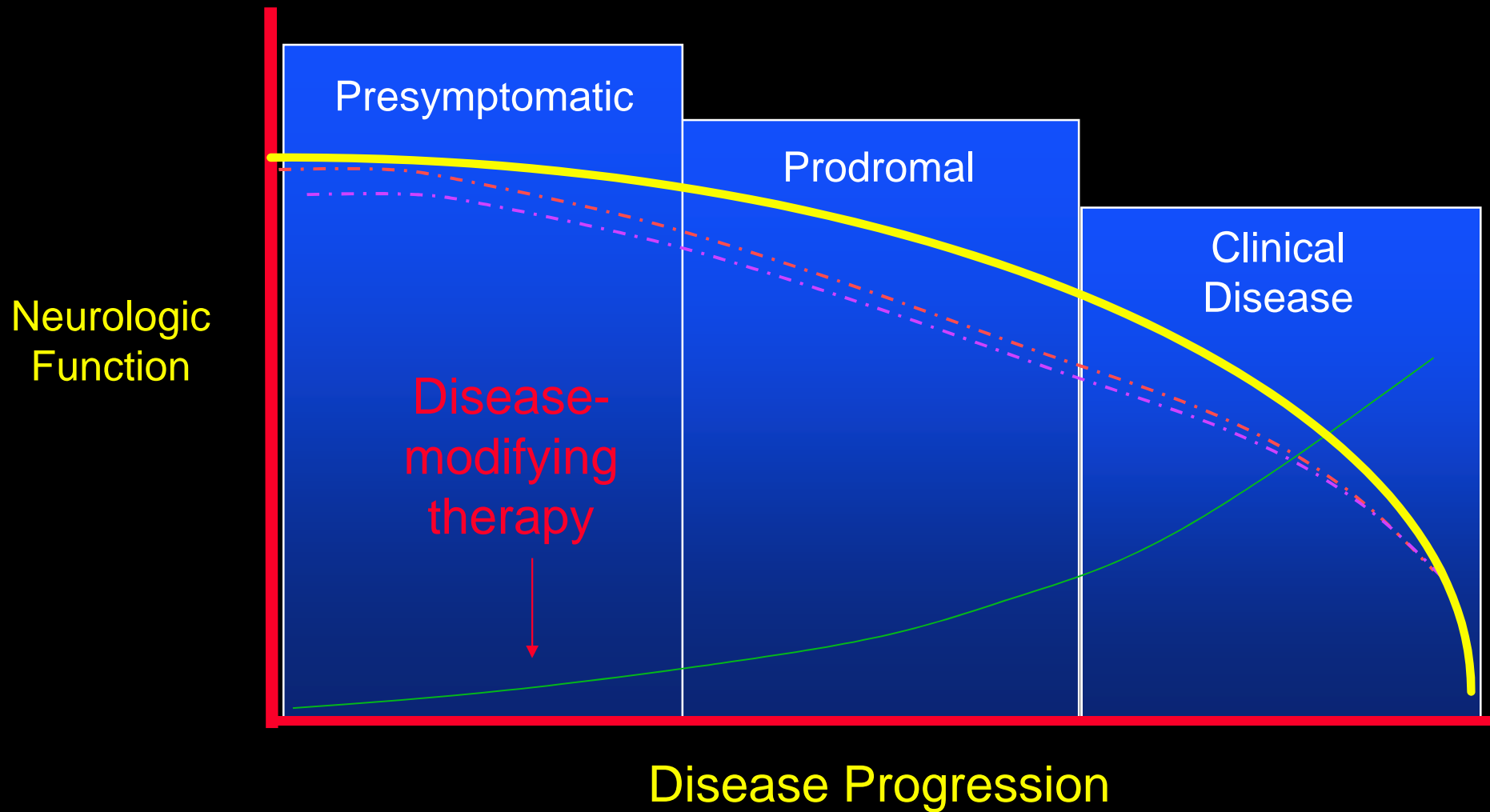
# Progression of neurodegenerative diseases



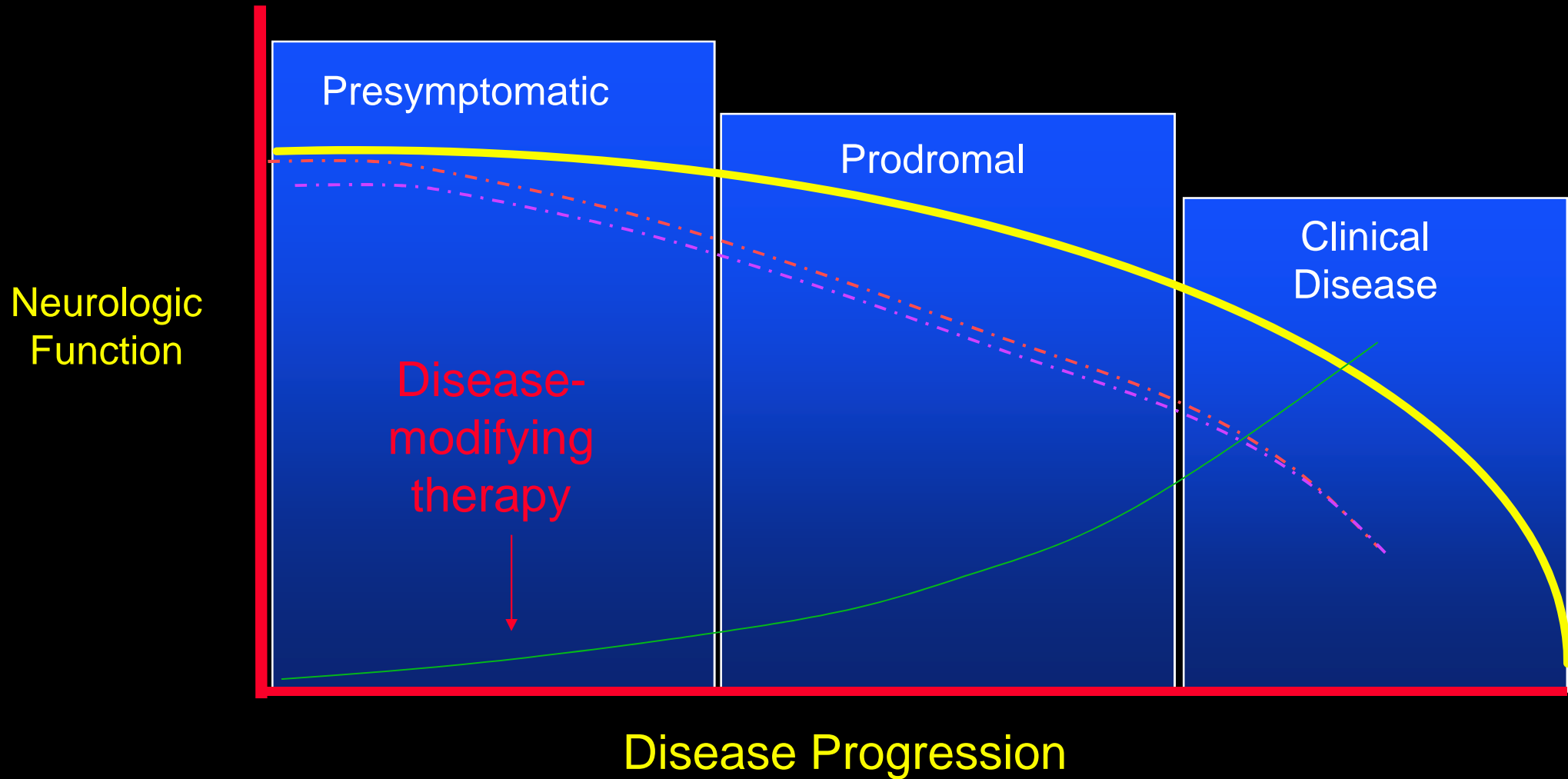
# Progression of neurodegenerative diseases



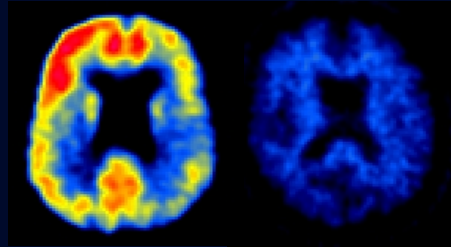
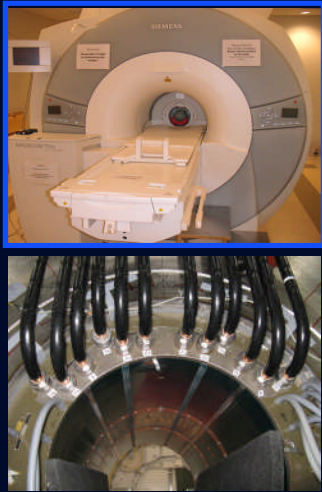
# Progression of neurodegenerative diseases



# Progression of neurodegenerative diseases



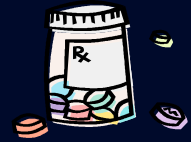
# Imaging Research for Novel Diagnostics/therapeutics and Better Care



Journal of Alzheimer's Disease 31 (2012) 1-12  
DOI: 10.3233/JAD-2012-120712  
IOS Press

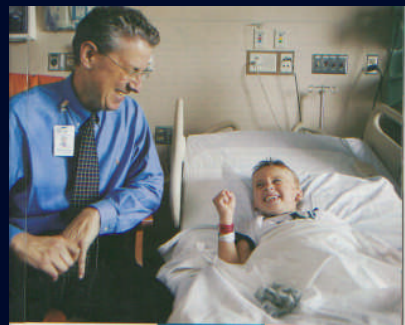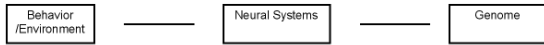
## A Highly Selective and Specific PET Tracer for Imaging of Tau Pathologies

Wei Zhang, Janna Arceaga, Daniel K. Cashion, Gang Chen, Umesh Gangadharmath, Luis F. Gomez, Dhanalakshmi Kasi, Chung Lam, Qianwa Liang, Changhui Liu, Vani P. Mocharla, Fanrong Mu, Anjana Sinha, A. Katrin Szardenings, Eric Wang, Joseph C. Walsh, Chunfang Xia, Chul Yu, Tieming Zhao and Hartmuth C. Kolb\*  
Siemens Molecular Imaging, Inc., Culver City, CA, USA



Automation and Databasing

Figure 4: Neural systems biology acts as an interface between behavior and the genome



Translational (from bench to bedside)



Translational (from experimental animal to human)



AGES

5 ← → 20 Prefrontal Cortex

Blue represents maturing of brain areas.

**THANK YOU!**